

---

To determine which sensory nerve conduction studies (S-NCS) are helpful in detecting supraclavicular axon loss brachial plexopathies, we selected 53 cases (of 417 reviewed) in whom complicating factors were absent and which, by needle electrode examination findings, involved only a single "truncal" element (upper, middle, or lower) of the brachial plexus. Extensive S-NCS included: median, recording thumb (Med-D1), index (Med-D2), and middle fingers (Med-D3); ulnar, recording fifth finger (Uln-D5); dorsal ulnar cutaneous, recording dorsum of the hand (DUC); radial, recording base of thumb; and both medial and lateral antebrachial cutaneous (MABC, LABC), recording forearm. Except for the median sensory fibers, the "cord" elements traversed by the sensory fibers assessed during the S-NCS listed above are anatomically defined (i.e., the sensory fibers enter the brachial plexus at only one cord). In regard to the median sensory fibers, however, there are two possible pathways through the infraclavicular plexus: (1) the lateral cord and/or (2) the medial cord. Because the lower trunk is only accessible via the medial cord, any sensory fibers found to be traversing the lower trunk had to first traverse the medial cord. Similarly, those traversing the upper and middle trunks must first be a component of the lateral cord. The frequency that the various S-NCS responses were abnormal (unelicitable, below laboratory normal value, or  $\leq 50\%$  of the contralateral response) for a given brachial plexus element lesion was as follows: (1) upper trunk (UT): 25 of 26 Med-D1, 25 of 26 LABC, 15 of 26 radial, 5 of 26 Med-D2, 2 of 26 Med-D3; (2) middle trunk (MT): 1 of 1 Med-D3; (3) lower trunk (LT): 25 of 26 Uln-D5, 22 of 23 DUC, 11 of 17 MABC, 3 of 23 Med-D3. With lower trunk brachial plexopathies, both "routine" (Uln-D5) and "uncommon" (DUC; MABC) S-NCS are abnormal. With upper trunk brachial plexopathies, in contrast, only the "uncommon" S-NCS (Med-D1; LABC) are consistently affected. The "routine" median S-NCS recording digit 2 (Med-D2) is far less reliable than the median S-NCS recording digit 1 (Med-D1) in detecting upper trunk axon loss brachial plexopathies. Additionally, the various pathways traversed by the fibers contributing to the individual S-NCS responses can be predicted, an important point when the full extent of a brachial plexus lesion is sought. © 1995 John Wiley & Sons, Inc.

Key words: brachial • plexus • sensory • nerve • conduction

MUSCLE & NERVE 18:879-889 1995

---

## THE UTILITY OF VARIOUS SENSORY NERVE CONDUCTION RESPONSES IN ASSESSING BRACHIAL PLEXOPATHIES

MARK A. FERRANTE, MD, and ASA J. WILBOURN, MD

---

From the EMG Laboratory, Neurology Department, Cleveland Clinic Foundation, Cleveland, Ohio.

This material was presented in part at the San Francisco AAEM meeting on 1 October 1994.

Acknowledgment: We would like to thank Robert W. Shields, Jr., MD, and Erik P.J. Pioro, MD, PhD, for their helpful criticisms and suggestions.

Address reprint requests to Asa J. Wilbourn, MD, Cleveland Clinic Foundation, EMG Department; Desk S-90, 9500 Euclid Avenue, Cleveland, OH 44195.

Accepted for publication March 15, 1995.

### INTRODUCTION

Dawson<sup>4</sup> introduced sensory nerve conduction studies (S-NCS) in 1956. He stimulated the digital nerves of the second and fifth fingers, while recording over the median and ulnar nerves at the wrist. In 1958, using these same orthodromic techniques, Gilliatt and Sears<sup>9</sup> showed that both the median and the ulnar sensory nerve action potentials (SNAPs) were unelicitable in the presence of diffuse axon loss brachial plexus (BP) lesions, while only the ulnar SNAP was affected by lower trunk

(LT) brachial plexopathies. Thus, they demonstrated that upper extremity S-NCS can be independently affected by focal brachial plexopathies. Nonetheless, most current textbooks and journal articles<sup>2,13,17,21,22,27,30</sup> concerned with the electrodiagnostic evaluation of the BP discuss upper extremity S-NCS primarily in regard to differentiating preganglionic (usually avulsion injuries) from postganglionic lesions, noting that the SNAP amplitudes are affected only by postganglionic axon loss. They also address electrodiagnostic evaluation of the terminal branch "elements" of the BP. Few sources, however, describe an approach for evaluating the various "internal" BP elements (i.e., trunks and cords), nor do they discuss the internal elements traversed by the sensory fibers studied during the various routine and uncommon S-NCS. Because none of the sensory fibers studied distally traverses all elements of the BP, it is not possible for a single S-NCS to assess the entire BP. Consequently, the individual S-NCS have the potential for providing localizing information with focal brachial plexopathies.

While some authors have mentioned only the routine S-NCS (i.e., median, stimulating/recording the index finger; ulnar, stimulating/recording the fifth finger) in regard to BP assessment,<sup>3,9</sup> others have discussed the importance of performing uncommon S-NCS for optimal assessment.<sup>1,6,18,24,25,31,32</sup> Still, there have been no series published to validate these claims, nor any attempt to identify the trunk elements evaluated by the routine and uncommon S-NCS. For this reason, we designed this study to determine the BP trunk element traversed by the sensory fibers studied during the various S-NCS, so that the latter can be logically utilized in the assessment of focal axon loss brachial plexopathies. Because lesions involving the terminal elements (i.e., branches) and preganglionic elements (i.e., roots) are well discussed in other sources, we did not seek to identify them. Moreover, the cord elements traversed by the sensory fibers of the S-NCS assessed distally are anatomically defined (e.g., the LABC nerve derives from the lateral cord, the radial nerve from the posterior cord, and the ulnar and MABC nerves from the medial cord). The exception to this is the median nerve, which is composed of fibers from both the lateral and medial cords. Still, because the upper and middle trunks can contain median sensory fibers derived only from the lateral cord, and similarly the lower trunk can receive sensory fibers solely from the medial cord, whenever sensory fibers are shown to traverse a particular

"trunk" element, the "cord" element they traverse is also defined.

## METHODS

We retrospectively evaluated all electrodiagnostic studies performed at the Cleveland Clinic Foundation over the past 11 years that had been coded as a brachial plexopathy ( $n = 417$ ). Our inclusion criterion was that each BP lesion be confined to a single "trunk" element (upper, middle, or lower), based on needle electrode examination (NEE), using established muscle domains (Table 1).<sup>12,15,16,23,26,33</sup> Our exclusion criteria were: (1) evidence of any BP abnormalities not confined to a single trunk element (as noted); (2) any other neuromuscular lesion(s) (e.g., coexisting carpal tunnel syndrome) in the affected limb; (3) plexopathies studied less than 21 days from weakness onset; and (4) any S-NCS abnormalities involving the contralateral limb; this latter exclusion criterion was applied because the SNAP responses were judged abnormal not only by their absolute values, but also by comparison to the SNAPs of the contralateral unaffected limb. Thus, changes in the contralateral S-NCS could obscure a S-NCS abnormality of the studied limb.

In our study, NEE of a muscle was considered abnormal if it showed evidence of acute and/or chronic motor axon loss (MAL). Acute MAL is reflected by the presence of fibrillation potentials and a decreased recruitment pattern, whereas chronic MAL is reflected by changes in the external configuration (e.g., increased duration and sometimes amplitude) and a decreased recruitment pattern. Generally, the average duration for a given muscle must be increased by at least 50% before we consider it to be abnormal. Utilizing the NEE of these 417 brachial plexopathies, we were able to identify 53 lesions confined to a single

**Table 1.** The muscle domains of the trunk elements.

Upper trunk	Middle trunk	Lower trunk
Supraspinatus	Pronator teres	Flex pollicis brevis
Infraspinatus	Flex carpi radialis	Abd pollicis brevis
Biceps	Triceps	Ext carpi ulnaris
Deltoid	Anconeus	Ext digit communis
Teres minor	Ext carpi radialis	Ext pollicis brevis
Triceps	Ext carpi ulnaris	Ext indicis proprius
Pronator teres	Ext digit communis	Flex carpi ulnaris
Flex carpi radialis	Ext indicis proprius	Flex digit prof-4,5
Brachioradialis		Abd digiti minimi
Ext carpi radialis		First dorsal inteross

*This table is modified from several published myotome charts (Refs. 12, 15, 16, 23, 26, 33).*

trunk element of the BP: 26 upper trunk (UT); 1 middle trunk (MT); and 26 lower trunk (LT).

The majority of BP lesions involving trunk elements were rejected from this study because more than a single trunk element was affected: combined UT and MT lesions, for example, were far more common than UT lesions alone, as were combined MT and LT lesions compared to LT lesions in isolation. Also, it is well known that MT lesions rarely occur in isolation, a point again confirmed by our study (discussed later). Thus, our rigid exclusion criteria necessitated rejection of approximately 87% of the brachial plexopathies reviewed.

Of the 53 EMG examinations accepted into this study, all had had the following "routine" S-NCS performed: median sensory response, recording digit 2 (Med-D2); ulnar sensory response, recording digit 5 (Uln-D5); and radial sensory response, recording dorsum of the hand (radial). Where applicable, additional "uncommon" S-NCS were performed (all antidromically), using published techniques.<sup>18</sup> These included median sensory responses, recording digit 1 (Med-D1) and digit 3 (Med-D3); dorsal ulnar cutaneous sensory response, recording dorsum of the hand (DUC); and medial and lateral antebrachial cutaneous sensory responses (MABC, LABC), recording forearm.

All the S-NCS responses performed in these 53 patients with unilateral BP lesions were evaluated. Peak-to-peak amplitudes were measured from the trough of the first positive component to the peak of the aftercoming negative component. In the event that an initial positivity was not apparent, then the response amplitude was measured from the baseline to the peak of the initial negative component. In our EMG laboratory we utilize malleable lead grounds (approximately 20 × 2.5 cm) to help reduce shock artifact. In the event that shock artifact is noted, we utilize standard approaches to eliminate it. In all of our 53 cases, shock artifact was not a significant problem. We never found it necessary to resort to such techniques as electronic averaging. Abnormalities were identified when the SNAPs were: (1) unelicitable; (2) lower in amplitude than the previously established age-related normal laboratory control values; or (3) ≤50% lower in amplitude than that obtained from the corresponding study on the contralateral limb. It was then determined what effect each BP lesion had on the various S-NCS performed. The borderline amplitude decrements (>40%, but <50%) identified in Table 2 were considered as "normals" for all calculations.

## RESULTS

Twenty-six UT lesions were identified using the NEE criteria outlined above. Both the LABC response and the Med-D1 responses were abnormal in 25 of 26 (96%) of these. The single "normal" Med-D1 response was borderline low in amplitude, when compared with the contralateral limb study. The radial response was abnormal in 15 of 26 (58%). The Med-D2 response was abnormal in only 5 of 26 (19%), and was of borderline low amplitude in an additional 3 instances. The Med-D3 response was abnormal in 2 of 26 (8%). The Uln-D5 response was normal in all. These results are listed in Table 2.

Only one MT lesion met the study criteria. The Med-D3 response was abnormal with it. The LABC, Med-D1, Med-D2, radial, and Uln-D5 responses were normal (in this single study), although the Med-2 response was borderline low (47% amplitude decrement when compared to the contralateral side). These results are also listed in Table 2.

Twenty-six LT lesions were identified. The Med-D3 response was abnormal in 3 of 23 (13%); of the 20 "normal" responses, 2 had borderline amplitude decrements (44%; 47%). Both the Uln-D5 and the DUC responses were abnormal in 96% (Uln-D5: 25 of 26; DUC: 22 of 23); the remaining Uln-D5 response showed a decrement of 43% when compared to the contralateral side, and was thus borderline low in amplitude. The MABC response was abnormal in 11 of 17 (65%) (see Discussion below). The following responses were within normal limits: LABC ( $n = 14$ ), Med-D1 ( $n = 20$ ), Med-D2 ( $n = 26$ ), and radial ( $n = 26$ ). These results are also listed in Table 2.

## DISCUSSION

As pointed out by Stewart,<sup>25</sup> knowing the origins of branches arising from the BP, and the muscles

**Table 2.** The incidence of abnormal S-NCS responses with various BP element lesions.

Abnormal response	UT	MT	LT
LABC	25/26	0/1	0/14
Med-D1	25/26	0/1	0/20
Med-D2	5/26	0/1*	0/26
Med-D3	2/26	1/1	3/23†
Radial	15/26	0/1	0/26
Uln-D5	0/26	0/1	25/26
DUC			22/23
MABC			11/17

\*The "normal" response revealed a 46% amplitude decrement in comparison to the other side.

†Two of the "normal" responses revealed borderline amplitude decrements (44%, 47%).

and cutaneous areas they supply, is important in the accurate localization of brachial plexopathies. Although S-NCS have been known to be useful in the electrodiagnostic evaluation of brachial plexopathies for over 35 years,<sup>9</sup> the potential for their anatomy to be applied electrodiagnostically has been underutilized. Axon loss lesions at the plexus level separate the sensory cell bodies in the dorsal root ganglia (DRG) from their peripheral projections (axons), causing the latter to undergo Wallerian degeneration. When these degenerated nerve fibers are a component of a sensory nerve assessed during S-NCS, they do not contribute to the SNAP and, consequently, its amplitude is decreased. With rather severe lesions the S-NCS responses become unelicitable. Because the sensory fibers assessed by a single S-NCS do not traverse all the BP elements, there is no single S-NCS capable of assessing all the BP elements simultaneously. Consequently, knowing the pathway through the plexus traversed by the sensory fibers assessed during S-NCS can be very helpful in BP evaluation.

Each of the 53 cases included in this study was selected because it had NEE abnormalities restricted to muscles within the domain of just a single trunk element, as determined by various standard myotome charts.<sup>12,15,16,23,26,33</sup> The NEE abnormalities included fibrillation potentials, frequently accompanied by a neurogenic motor unit potential (MUP) firing pattern (decreased recruitment), and sometimes by chronic neurogenic MUP changes. The degree of acute versus chronic MAL is a reflection of the temporal relationship between the onset of symptoms and the time the NEE was performed. As stated previously, all studies were performed at least 3 weeks after the onset of weakness. Given that the S-NCS responses are much more susceptible to pathologic insult than are the M-NCS responses, the acuteness or chronicity of the NEE findings does not adversely influence our interpretation.

Table 1 shows the muscle domains for the 3 trunk elements of the BP. It was derived from previously published studies<sup>12,15,16,23,26,33</sup> dealing with the muscle domains of various root (i.e., anterior primary rami, APR) elements. Except for the relatively few peripheral nerves arising from the APR level of the BP (e.g., dorsal scapular nerve, long thoracic nerve), the trunk elements of the BP are direct continuations of the APR (i.e., the UT is formed by the fusion of the C5 and C6 APR, the MT is a direct continuation of the C7 APR, and the LT is formed by the fusion of the C8 and T1 APR).<sup>14</sup> Thus, the muscle domain of a

given trunk element is equal to the muscle domain(s) of its contributing APR, *minus* the muscle domain(s) of the peripheral nerves (if any) given off at the APR level of the BP. The overlap in our table, like the overlap in the studies from which it was derived, reflects the fact that essentially all of the muscles sampled on NEE receive multisegmental innervation. Thus, in order to accurately localize axon loss BP lesions, one must be familiar with the muscle domains of all the BP elements. For example, if we noted NEE abnormalities in the supraspinatus, infraspinatus, deltoid, biceps, brachioradialis, and pronator teres muscles, the lesion was considered an UT brachial plexopathy. All of the above muscles receive motor axons from the C5 and C6 segments of the spinal cord, except for the pronator teres, which receives motor axons from the C6 and C7 segments. Thus, motor axons innervating the pronator teres traverse both the UT and the MT. Given that no abnormalities were noted in any other muscles of the MT muscle domain, we considered it unlikely that the lesion was affecting both the UT and the MT; rather, we assumed it involved the UT in isolation and the pronator teres contained fibrillation potentials because of its C6/UT innervation. A second, more complex example of this reasoning process, is that of the single MT lesion identified in this study. Note in Table 1 that 4 of the muscles listed in the MT muscle domain are also listed in the UT muscle domain, and that 3 of them also appear in the LT muscle domain. Because it lies between 2 other trunk elements, its muscles are for the most part "shared." It becomes important, therefore, to sample the "unshared" muscles of both the upper and lower trunks. If they are all spared, and only if they are all spared, then the possibility that the lesion is a mixed trunk element lesion is quite remote, since it is very unlikely that involvement of a second trunk element would affect only those motor nerve fascicles innervating muscles found in both domains, while sparing the "unshared" muscles. Our MT case went to surgery, based in part on our electrodiagnostic examination, and was found to have a fibrotic process of unknown etiology involving solely the MT. The overlap seen in the MT muscle domain is analogous to that seen in the C7 APR muscle domain (as expected given that it is a direct continuation of that root), and we are unaware of any electromyographers who consider it impossible to make a diagnosis of a C7 radiculopathy. Thus, the rarity of an isolated MT lesion is not due to the complexity involved in making the electrodiagnosis. Although the muscle domains of

the BP elements overlap, the "shared" muscles are important in evaluating the full extent of a brachial plexopathy, so we elected to utilize them in our search for focal lesions. Moreover, we were concerned that excluding such lesions would result in a selection bias toward more partial (i.e., less severe) BP element lesions. Less severe lesions would be more likely to spare the sensory fibers studied by the various S-NCS and could adversely affect our results.

We are well aware of the limitations of this approach. First, variations in BP anatomy (both vertical and horizontal variations) could conceivably have an effect on both the NEE and the NCS findings.<sup>5,10,28,34,35</sup> Perhaps the most discussed BP anomaly is that of pre- and post-fixation.<sup>29</sup> It is interesting to note, however, that with these vertical anomalies, while the root contribution of the trunk elements changes, the plexus arrangement itself remains the same. Thus, although the sensory fibers derive from an adjacent DRG (either the one above or the one below the "typical" DRG), the pattern of NCS and NEE abnormalities would localize to the same BP element. Regarding horizontal variations, Leffert<sup>14</sup> has reported that the trunk elements are seldom anomalous, the MT being a direct extension of the C7 APR in 100%, and the UT and LT being of "classical" formation in >90% and >95%, respectively.

A second limitation of this study is that we often were unable to verify that the BP trunk element identified electrodiagnostically was truly the pathological site of involvement. Neuroimaging studies (which were not performed on all patients) usually were not helpful because they are not sensitive enough to permit lesion identification confined to a single trunk element. Similarly, operative verification that only one BP element was involved was not possible because only a minority of our patients underwent surgical exploration (e.g., the MT case). Yet electromyographers are called upon to assess all BP lesions, regardless of whether or not they are surgically explored. Moreover, even if all patients underwent surgical confirmation, electrodiagnostic evaluation would still be required preoperatively, and thus the dilemma would remain. We, like other authors before us, did the next best thing. We correlated all of our electrodiagnostic impressions with the clinical examinations. In addition to credible histories of a focal BP lesion, all 53 cases had clinical examination features consistent with involvement of the BP element ultimately diagnosed by NEE. The NEE either confirmed the clinical impression or further refined it.

While our brachial plexopathy series represents a biased population (i.e., focal brachial plexopathies), their etiologies were varied: trauma (18), true neurogenic thoracic outlet syndrome (10), post median sternotomy (open heart surgery) (7), neoplastic (4), neuralgic amyotrophy (3), post irradiation treatment (1), iatrogenic (1), neurofibromatosis type I (1), and unknown (8). Of note is that in the 3 patients with neuralgic amyotrophy, both the clinical and NEE features were suggestive of an UT BP lesion and not, as is more often the case, one or more proximal mononeuropathies.<sup>7</sup>

The individual S-NCS and the likely course of their sensory fibers through the BP will next be discussed.

**The LABC Response.** The lateral antebrachial cutaneous nerve is the terminal portion of the musculocutaneous nerve, derived from the LC of the BP. Consequently, by anatomical definition, the "cord" element traversed by the sensory fibers assessed by the LABC S-NCS is the lateral cord. Thus only LC lesions, but not PC or MC lesions, have the potential to affect the LABC S-NCS at the "cord" level of the BP. With regard to the trunk elements that the LABC fibers traverse, they could traverse the upper trunk, the middle trunk, or both. Since the LABC response was abnormal in 25 of 26 UT lesions, our results suggest that they traverse predominantly the UT. Our study did not adequately assess the MT, since only one MT lesion was identified. However, Inouye and Buchthal<sup>11</sup> recorded spinal nerve potentials evoked by stimulation of the sensory fibers of the musculocutaneous nerve and showed that the maximum amplitude occurred at the C6 root, while Yoss and coworkers<sup>35</sup> have shown that C6, but not C5, radiculopathies cause sensory symptoms in the lateral forearm (i.e., in the sensory distribution of the LABC nerve). These studies support our finding that the predominant course taken through the BP for those sensory fibers assessed by the LABC S-NCS is the LC and the UT. They also suggest that the sensory axons assessed by the LABC SNAP have their cell bodies of origin in the C6 DRG cells. Importantly, the LT element of the BP is not assessed by the LABC sensory response (nor are the MC or PC). Figure 1 illustrates the suggested pathway.

**The Med-D1 Response.** The median nerve is composed of fibers derived from both the LC and the MC. Because the Med-D1 response was abnormal in 25 of 26 UT lesions, 0 of 1 MT lesion, and 0 of

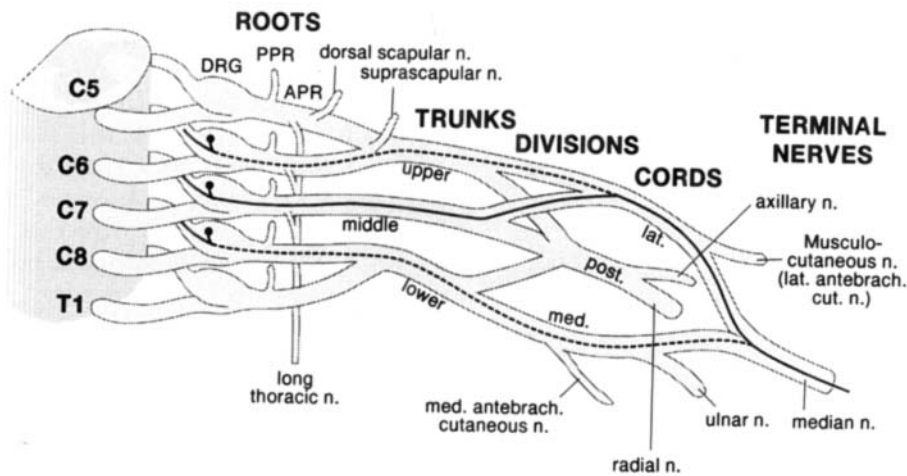


FIGURE 1. Proposed brachial plexus pathway for the sensory fibers assessed by the LABC SNAP.

20 LT lesions, our study suggests that the Med-D1 SNAP is elicited from fibers that traverse the UT (and LC). Whether or not some of the fibers it assesses sometimes traverse the MT could not be determined by this study because only a single MT lesion was identified. Of importance is that the LT, MC, and PC elements of the BP are not assessed by the Med-D1 sensory response. Figure 2 illustrates the suggested pathway.

**The Med-D2 Response.** The Med-D2 SNAP was abnormal in 5 of 26 UT lesions, although 3 of 21 “normal” responses were borderline low in amplitude when compared to the contralateral side (see Table 2). The Med-D2 SNAP was abnormal with 0 of 1 MT lesion, but this response was borderline low in amplitude (47%) compared to that found in the contralateral limb (see Table 2). The Med-D2 SNAP was abnormal with 0 of 26 LT lesions. Even

though only one MT lesion was available for evaluation (borderline low in amplitude), the absolute lack of involvement of the Med-D2 SNAP with LT lesions coupled with the rather minimal involvement (32% at most, if borderline low amplitudes are included as abnormal) with UT lesions suggests, by default, that the MT is the trunk element most often traversed by the sensory fibers supplying the index finger. However, due to the limited number of MT lesions in our study, no definite conclusions can be drawn. Nonetheless, it is pertinent to note that while we were collecting the 53 isolated trunk element lesions included in this study, we rejected dozens of plexopathies in which the Med-D2 response was abnormal because, on NEE, abnormalities were present outside of the predefined MT muscle domain (i.e., they were UT/MT or MT/LT lesions). Thus, the Med-D2 response assesses the UT in a minority of patients,

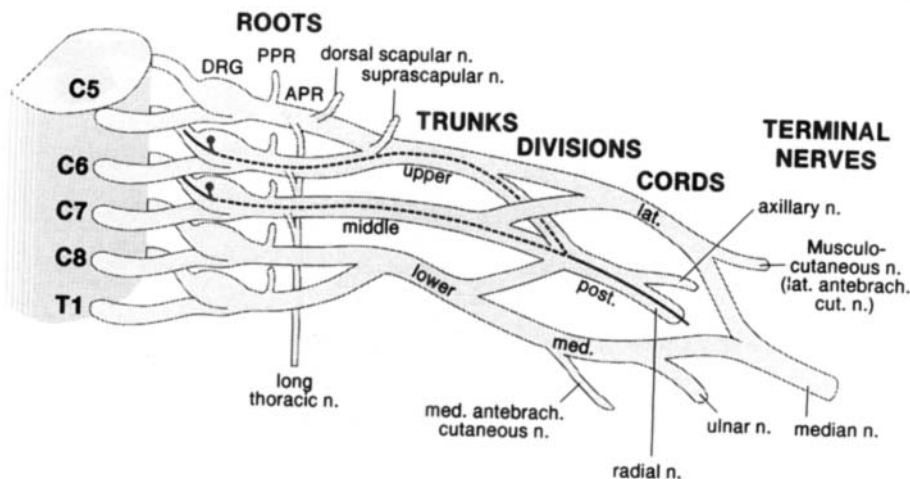


FIGURE 2. Proposed brachial plexus pathway for the sensory fibers assessed by the Med-D1 SNAP.

presumably the MT in most patients, and the LC in all patients. Importantly, the LT (along with the MC and the PC) element is not assessed by the Med-D2 response. Figure 3 illustrates the suggested pathway.

**The Med-D3 Response.** The Med-D3 SNAP was abnormal in 2 of 26 UT lesions, 1 of 1 MT lesion, and 3 of 23 LT lesions (2 of the 20 “normal” with LT lesions were borderline low in amplitude, 44% and 47%, compared to the other side) (see Table 2). These findings suggest that the sensory fibers supplying the middle finger can traverse the UT, MT, and/or LT elements. Because our study showed that the Med-D3 response was seldom affected with isolated UT lesions, it is probable that the sensory axons subserving this response derive primarily from the C7 DRG and therefore traverse the MT. However, because only one isolated MT lesion was included in this study, no definite conclusions are possible. Nonetheless, analogous to the circumstances surrounding the Med-D2 response, we found that the Med-D3 response was typically abnormal with combined UT and MT brachial plexopathies, as well as with combined MT and LT lesions. This again suggested that the MT is the predominant trunk element traversed by the sensory fibers contributing to the Med-D3 SNAP. The major difference between the Med-D2 and the Med-D3 responses was that the latter was abnormal with 13% of the LT lesions, revealing, contrary to past beliefs, that the median sensory axons contributing to the Med-D3 SNAP sometimes pass through the MC and the LT elements of the BP on their way to their DRG cell bodies of origin. The suggested pathways are shown in Figure 4.

**The Radial Responses.** The radial sensory response was abnormal with 15 of 26 (58%) lesions involving the UT, 0 of 1 affecting the MT, and 0 of 26 involving the LT. As with the Med-D2 and Med-D3 responses, accurately determining the MT contribution was not possible, because only 1 MT lesion was identified. However, the fact that the radial SNAP was abnormal in only 58% of UT lesions suggests that this is not the only trunk element these fibers traverse. Moreover, the fact that the radial SNAP was normal in all 26 LT lesions indicates that the LT is not the additional trunk element traversed. By default, these results suggest that the MT serves as an important conduit for radial sensory fibers approximately 42% of the time. Supporting this concept is that the radial SNAP frequently was abnormal both with combined UT/MT lesions and with combined MT/LT lesions, two categories of BP lesions not included in this study. This concept is also supported by the work of Inouye and Buchthal,<sup>11</sup> who showed that the maximum amplitude response with radial nerve stimulation occurred at the C6 and C7 roots, suggesting that the UT and MT function as pathways for these fibers. Thus, the radial sensory fibers appear to traverse both the UT and the MT (the particular pathway varying from patient to patient) as well as the PC. Importantly, the radial sensory fibers do not traverse the LT, MC, or LC. Figure 5 depicts the suggested pathways.

**The Uln-D5 and DUC Responses.** By anatomic definition, the sensory fibers contributing to the Uln-D5 and the DUC SNAPs must traverse the MC and the LT BP elements. Thus, it is not surprising that the Uln-D5 SNAP was abnormal in 25 of 26 LT

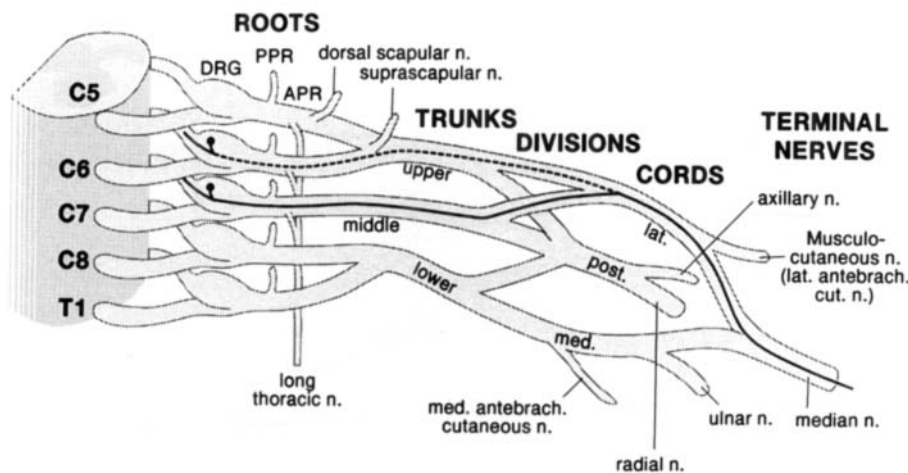


FIGURE 3. Proposed brachial plexus pathway for the sensory fibers assessed by the Med-D2 SNAP.

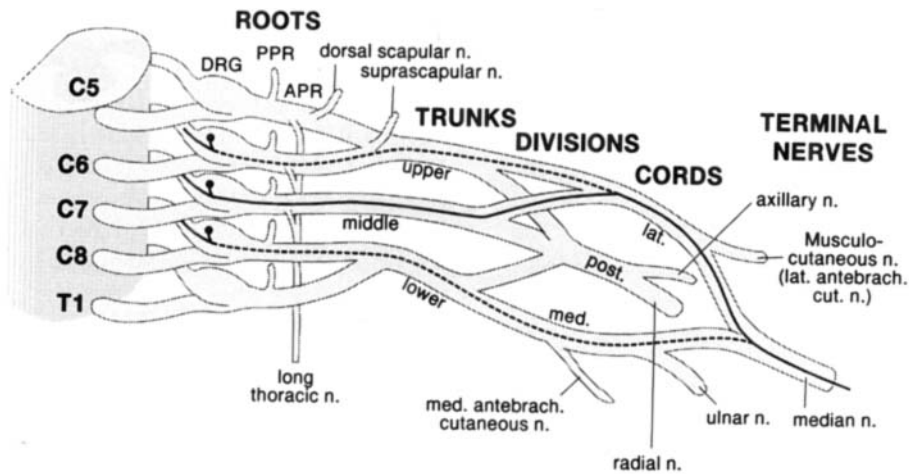


FIGURE 4. Proposed brachial plexus pathway for the sensory fibers assessed by the Med-D3 SNAP.

lesions, with the only “normal” response showing a borderline amplitude decrement compared to the other side. The DUC SNAP was abnormal in 22 of 23 LT lesions. Thus, our results confirm the undisputed fact that the Uln-D5 and DUC SNAPs evaluate the MC and LT elements of the BP; they do not assess the UT, MT, LC, or PC.

We did not perform a DUC S-NCS on any of our UT patients, because the sensory fibers subserving this response are known not to traverse the UT, and the studies, as is, were already quite time-consuming. Moreover, as these data show, the DUC S-NCS response was always abnormal whenever the Uln-D5 S-NCS response was abnormal; and we did perform an Uln-D5 S-NCS in all 53 of these patients (and thus in all 26 of the UT lesions). As suspected, it was never involved.

**The MABC Response.** The medial antebrachial cutaneous nerve originates from the MC, which is

continuous with the LT. By anatomical definition, the MABC SNAP should assess fibers that traverse the LT element of the BP. Our study confirmed this, showing abnormal MABC SNAPs in 11 of 17 LT lesions. However, a pertinent question arises: “Why were only two thirds of the MABC sensory responses affected by the LT lesions if this is the only trunk element traversed by these sensory fibers?” First, it is important to note that all the LT plexopathies in which the normal MABC response occurred had the same etiology: postmedian sternotomy. These particular LT plexopathies (i.e., those associated with median sternotomy) differ from most other LT lesions in that they consistently affect the ulnar motor and sensory fibers disproportionately more than they affect the C8/T1 median motor fibers and the MABC fibers. We believe this occurs because these lesions actually involve primarily the C8 APR rather than the LT itself. Conversely, we believe that the lesion char-

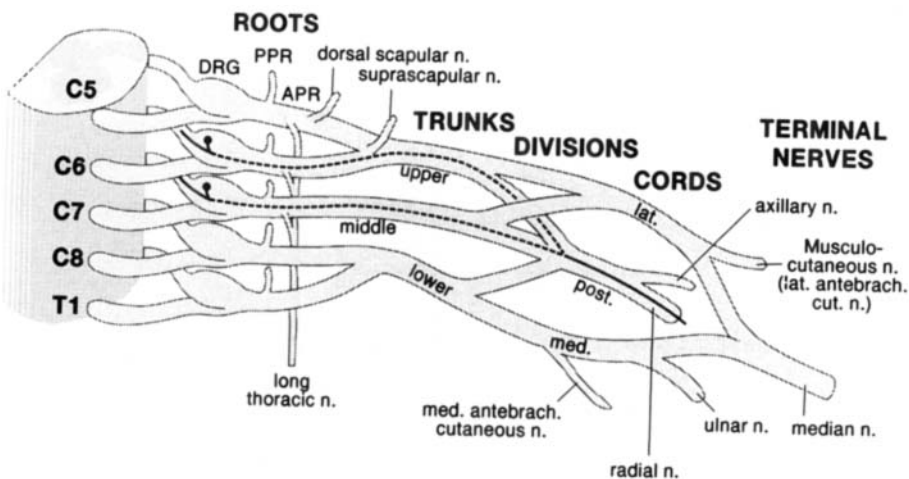


FIGURE 5. Proposed brachial plexus pathway for the sensory fibers assessed by the radial SNAP.



acteristic of true neurogenic thoracic outlet syndrome (TN-TOS) actually involves primarily the T1 APR rather than the LT. Both Maggiano et al.<sup>19</sup> and Nishida et al.,<sup>20</sup> in separate reports dealing almost exclusively with TN-TOS, have reported consistently finding MABC response abnormalities with these lesions. The operative results Gilliatt reported (34 patients) are also consistent with this conclusion<sup>8</sup>; he noted that usually the C8 and T1 APR crossed the congenital taut band (extending from the tip of the rudimentary cervical rib to the first thoracic rib) and that the T1 APR appeared to be more affected. With TN-TOS the electrodiagnostic findings are typically the opposite of those found with postmedian sternotomy: the median motor NCS and the MABC NCS are severely involved, while the ulnar sensory NCS, and particularly the ulnar motor NCS, are less affected. Thus in TN-TOS, the ulnar sensory NCS response, while absolutely or relatively low in amplitude, is rarely unelicitable, whereas the MABC response is typically unelicitable. We did not perform a MABC S-NCS in any of the UT cases because it would be anatomically impossible for these fibers to traverse that element of the BP.

## CONCLUSIONS

A number of conclusions regarding both the anatomy of the BP and the optimal method for assessing it with S-NCS can be derived from this study.

Regarding anatomy, some previously held concepts apparently are incorrect regarding the various BP elements traversed by the median sensory

fibers supplying the digits. First, the index finger digital nerves seldom derive from the UT. By default, it appears that they usually originate from the C7 DRG cells, and pass through the MT to the LC, rather than arising from the C6 DRG cells and traversing the UT to the LC. Second, probably not all the median digital nerve fibers traverse the lateral cord. The fact that the Med-D3 SNAP occasionally (13%) was abnormal with LT lesions, suggests that the middle finger is sometimes supplied by median sensory fibers derived from the C8 DRG, via the LT and MC elements of the BP.

Regarding the optimal use of the S-NCS for assessing brachial plexopathies, we conclude the following:

1. With possible UT lesions, the routine Med-D2 study is inadequate. Either the LABC SNAP, the Med-D1 SNAP, or both, should be performed. In our EMG laboratory, we usually perform a combination of motor and sensory NCS (our "UT package") consisting of the LABC sensory, the Med-D1 sensory, the musculocutaneous motor (recording biceps), and the axillary motor (recording deltoid) studies. Our routine assessment also includes the radial SNAP, which may also be helpful in approximately 58% of UT lesions.
2. With possible MT lesions, the Med-D2 and the Med-D3 S-NCS appear to be optimal; although the radial S-NCS may also be abnormal (42%).
3. With possible LT or MC lesions only one ulnar S-NCS, Uln-D5 or DUC, needs to be

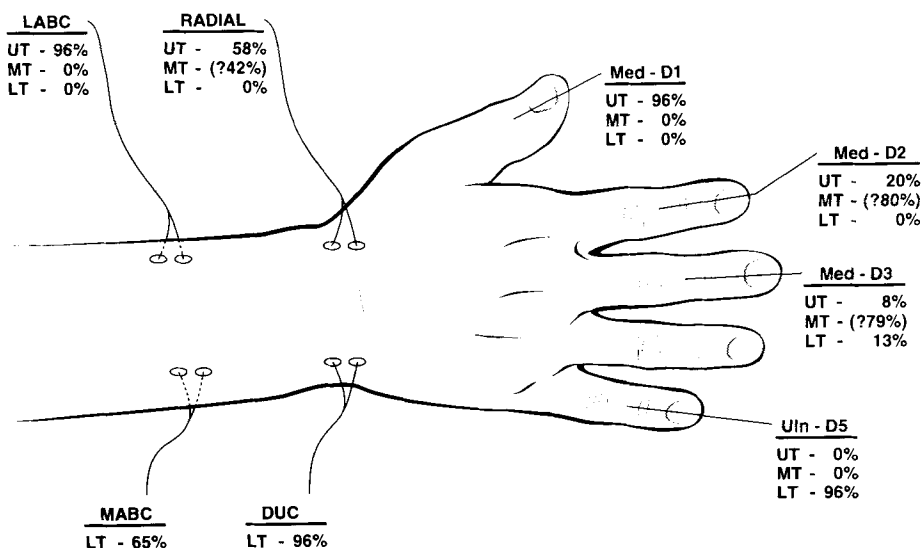


FIGURE 6. Illustration of the incidence of S-NCS involvement for the supraclavicular brachial plexus elements.

performed since the axons assessed by both traverse identical BP elements and therefore yield identical results. Except for lesions resulting from median sternotomy, the MABC S-NCS is also an excellent S-NCS for assessing these BP elements. In our EMG laboratory, we usually perform a combination of S-NCS and M-NCS when assessing patients with possible LT/MC lesions (our "LT package") consisting of the following: Uln-D5, MABC, median motor (recording APB), and ulnar motor (recording ADM and frequently FDI as well). We have recently omitted the DUC response because, in this study, its results so closely paralleled the results of the Uln-D5 response.

4. Although the Med-D4 sensory response was not utilized in this study, it may be useful for demonstrating LT brachial plexopathies. Conceivably, it could be very helpful in differentiating LT lesions from ulnar nerve lesions in the postmedian sternotomy patients with LT plexopathies predominantly affecting ulnar nerve fibers. This is the population of LT lesions in which the MABC response is notoriously spared, probably because the lesion actually involves the C8 APR.
5. With possible LC lesions, the LABC, Med-D1, Med-D2, and usually the Med-D3 responses should be affected while the radial response should always be unaffected.

Thus, like the muscle domains of the individual BP elements, there exist S-NCS domains for each of the BP elements (see Fig. 6). Although there also exist M-NCS domains for each of the BP elements, they are not as helpful for localization due to the limited number of M-NCS available and to their considerable overlap. We find M-NCS to be more useful in assessing the severity of the lesion (a direct reflection of their amplitude decrements).

## REFERENCES

1. Aminoff MJ, Olney RK, Parry GJ, Raskin NH: Relative utility of different electrophysiologic techniques in the evaluation of brachial plexopathies. *Neurology* 1988;38:546-550.
2. Benecke R, Conrad B: The distal sensory nerve action potential as a diagnostic tool for the differentiation of lesions in dorsal roots and peripheral nerves. *J Neurol* 1980;223:231-239.
3. Daube JR: Nerve conduction studies, in Aminoff MJ (ed): *Electrodiagnosis in Clinical Neurology*, 2nd ed. New York, Churchill Livingstone, 1986, pp 265-306.
4. Dawson GD: The relative excitability and conduction velocity of sensory and motor nerve fibers in man. *J Physiol* 1956;131:436-444.
5. DeJong RN: *The Neurological Examination*, 2nd ed. New York, Hoeber and Harper, 1958, p 737.
6. Eisen AA: The electrodiagnosis of plexopathies, in Brown WF, Bolton CF (eds): *Clinical Electromyography*, 2nd ed. Boston, Butterworth-Heinemann, 1993, pp 211-226.
7. England JD, Sumner AJ: Neuralgic amyotrophy: an increasingly diverse entity. *Muscle Nerve* 1987;10:60-68.
8. Gilliatt RW: Thoracic Outlet Syndromes, in Dyck PJ, Thomas PK (eds): *Peripheral Neuropathy*, 2nd ed. Philadelphia, Saunders, 1984, pp 1409-1419.
9. Gilliatt RW, Sears TA: Sensory nerve action potentials in patients with peripheral nerve lesions. *J Neurol Neurosurg Psychiatry* 1958;21:109-118.
10. Goss CM: *Gray's Anatomy*, 29th American edition. Philadelphia, Lea and Febiger, 1973, p 962.
11. Inouye Y, Buchthal F: Segmental sensory innervation determined by potentials recorded from cervical spinal nerves. *Brain* 1977;100:731-748.
12. Kendall FP, McCreary EK, Provance PG: *Muscles: Testing and Function*, 4th ed. Baltimore, Williams and Wilkins, 1993, pp 406-407.
13. Kimura J: Assessment of individual nerves, in *Electrodiagnosis in Diseases of Nerve and Muscle: Principles and Practice*, 2nd ed. Philadelphia, Davis, 1989, pp 103-123.
14. Leffert RD: *Brachial Plexus Injuries*. New York, Churchill Livingstone, 1985, pp 1-39.
15. Liveson JA: *Peripheral Neurology: Case Studies in Electrodiagnosis*. 2nd ed. Philadelphia, Davis, 1992, pp 36-42.
16. Liveson JA, Ma DM: *Laboratory Reference for Clinical Neurophysiology*. Philadelphia, Davis, 1991, pp 415-423.
17. Liveson JA, Ma DM: *Laboratory Reference for Clinical Neurophysiology*. Philadelphia, Davis, 1992, pp 43-162.
18. Ma DM, Wilbourn AJ, Kraft GH: Unusual sensory conduction studies (2nd ed), an American Association of Electrodiagnostic Medicine Workshop; Rochester, MN, AAEM, 1992, pp 1-15.
19. Maggiano H, Levin KH, Wilbourn AJ: Relationship between the medial antebrachial cutaneous sensory and median motor responses in brachial plexopathies [abstract]. *Muscle Nerve* 1993;16:1113-1114.
20. Nishida T, Price SJ, Minieka MM: Medial antebrachial cutaneous nerve conduction in true neurogenic thoracic outlet syndrome. *Electromyogr Clin Neurophysiol* 1993;33:285-288.
21. Oh SJ: Anatomical guide for common nerve conduction studies, in *Clinical Electromyography Nerve Conduction Studies*, 2nd ed. Baltimore, Williams and Wilkins, 1993, pp 56-64.
22. Olney RK, Wilbourn AJ: Sensory nerve conduction study workshop, in Course 150, American Academy of Neurology Annual Meeting, 1993.
23. Perotto AO: *Anatomical Guide for the Electromyographer: The Limbs and Trunk*, 3rd ed. Springfield, Charles Thomas, 1994, pp 305-307.
24. Rubin M, Lange DJ: Sensory nerve abnormalities in brachial plexopathy. *Eur Neurol* 1992;32:245-247.
25. Stewart JD: *Focal Peripheral Neuropathies*. New York, Elsevier, 1987, p 97.
26. Stewart JD: *Focal Peripheral Neuropathies*, 2nd ed. New York, Raven Press, 1993, p 113.
27. Sunderland S: *Nerves and Nerve Injuries*. New York, Churchill Livingstone, 1978, pp 854-869.
28. Sunderland S: *Nerves and Nerve Injuries*. New York, Churchill Livingstone, 1978, p 862.
29. Swash M: Diagnosis of brachial root and plexus lesions. *J Neurol* 1986;233:131-135.
30. Wilbourn AJ: Electrodiagnosis of plexopathies. *Neurologic Clinics* 1985;233:131-135.
31. Wilbourn AJ: Iatrogenic brachial plexopathies: Clinical

- and EMG features. In 1990 American Association of Electrodiagnostic Medicine Course D: *Electrodiagnosis of Iatrogenic Neuropathies*. Rochester, MN, AAEM, 1990, pp 10–21.
32. Wilbourn AJ: Brachial Plexus Disorders, in Dyck PJ, Thomas PK (eds): *Peripheral Neuropathy*, 3rd ed. Philadelphia, Saunders, 1993, pp 911–950.
33. Wilbourn AJ, Aminoff AJ: Radiculopathies, in Brown WF, Bolton CF (eds): *Clinical Electromyography*, 2nd ed. Boston, Butterworth-Heinemann, 1993, pp 175–205.
34. Williams PL, Warwick R (eds): *Gray's Anatomy*, 36th British edition. New York, Churchill Livingstone, 1980, pp 1094–1095.
35. Yoss RE, Kendall BC, MacCarty CS, Love JG: Significance of symptoms and signs in localization of involved root in cervical disk protrusion. *Neurology* 1957;7:673–683.