

Abdul-Wahab T. Al-Khodairy
Philippe Bovay
Charles Gobelet

Sciatica in the female patient: anatomical considerations, aetiology and review of the literature

Received: 24 June 2005
Revised: 22 January 2006
Accepted: 25 January 2006
Published online: 19 April 2006
© Springer-Verlag 2006

A.-W. T. Al-Khodairy (✉)
P. Bovay · C. Gobelet
Clinique romande de
réadaptation-suvacare,
Sion, Switzerland
E-mail: abdul.al-khodairy@crr-suva.ch
Tel.: +41-27-6032135
Fax: +41-27-6033031

Abstract The principal author was confronted few years ago with the case of a 38-year-old woman with a 5-month history of ill-defined L5 sciatic pain that was referred to an orthopaedic department for investigation and eventual surgical treatment for what was suspected to be herniated disc-related sciatica. Removal of her enlarged uterus found unexpectedly close to the sacroiliac joint upon lumbar MRI abolished her symptoms. Review of the literature showed that the lumbosacral trunk is vulnerable to pressure from any abdominal mass originating from the uterus and the ovaries. Physiological processes in the female patient and gynaecologi-

cal diseases may be the source of sciatica, often not readily searched for, leading to fruitless investigations and surgical treatments. The aim of the paper is to highlight gynaecological and obstetrical causes of sciatica and sciatica-like symptoms. To prevent unproductive expenses and morbidity, a thorough gynaecological examination should be done even though neurological examination may be suggestive of a herniated intervertebral disc, and the cyclic pattern of pain related to menses should be routinely asked for.

Keywords Sciatica · Sciatic neuropathy · Female · Pregnancy complications · Endometriosis

Introduction

Sciatica secondary to nerve root compression usually presents with well-defined distal motor and sensory involvement and reflex changes. As the dura, nerve roots, and their sleeves are sensitive to pain, dural mobility tests may help in the diagnosis of sciatica [41, 66, 79, 96]. In lumbosacral plexopathy, several roots may be involved with a patchy distribution with no clear anatomical localisation [22, 30].

Disc prolapse is by far the most popular and common cause of sciatica with lesions occurring most often at L4-L5 and L5-S1 segments [79]. The vulnerability of the lumbosacral plexus (L4-L5 roots) to compression by uterine and pelvic tumours has led to misdiagnosis and ineffective surgeries in the past. This article attempts to give to the reader an overview of the literature so as to

prevent such misadventures and help in prompt diagnosis and management.

Material and methods

The courses of the lumbosacral plexus and sciatic nerve were reviewed with special emphasis on their relation to female pelvic organs. The Medline database was screened through the period 1966–2004 February using sciatica, sciatica and female patients, or sciatica and aetiology as key words. Articles describing sciatica related to gynaecological, obstetrical, or anatomical variations in the female patient were selected and studied. Articles published before 1966 and referred to in articles were obtained and carefully studied as well.

Results

The first three and most of the fourth lumbar ventral rami descend laterally into the psoas major muscle and form the lumbar plexus [127, 171]. The smaller moiety of the fourth joins the fifth as the lumbosacral trunk that appears at the medial margin of the psoas major, descending over the pelvic brim anterior to the sacroiliac joint to join the first three sacral rami and part of S4 forming the sacral plexus (Fig. 1).

The sacral plexus adjoins the posterior pelvic wall anterior to the piriformis muscle, posterior to the internal iliac vessels, the ureter, and the sigmoid colon to the left and the terminal ileal coils on the right. The sciatic nerve is the continuation of the upper band of the sacral plexus. It leaves the pelvis via the greater sciatic foramen usually situated between the deeper gemelli and obturator internus and the superficial piriformis muscles and descends along the back of the thigh dividing into the tibial and common (fibular) peroneal nerves. The close proximity of the piriformis makes the sciatic nerve vulnerable to irritation and entrapment [11]. Sometimes, the common peroneal portion of the sciatic nerve, and rarely the entire nerve, pierces through the piriformis muscle that may be bipartite entrapping the sciatic nerve [32, 157].

Seventy-five articles in English, French, German, Spanish, and Danish reporting 127 cases with unilateral or bilateral sciatica or leg pain caused by a gynaecological or an obstetrical disorder were found. Endometriosis was the commonest cause (66) followed by pregnancy and labour related sciatica (40), fibroids (4), sacral osteophytes (3), endosalpingiosis (3), vaginal

needle intervention (2), pelvic metastasis (2), piriformis related sciatica (2) and one case each related to adenomyosis, intra-uterine device, haematocolpos, tuboovarian abscess, and retroverted uterus.

Sciatica in pregnancy

Back pain is reported by as many as 50–76% of all pregnant women, generally as a musculoskeletal response to the shifting centre of gravity, weight gain and hormonal factors responsible for ligamentous relaxation and changes in the pelvic joints [99, 165, 170].

At term, the *gravid uterus* averages about 5 l and weighs approximately 1,100 gm to be added to the average infant birth weight of 3,000–3,600 gm [37]. The largest baby recorded in the literature was a stillborn female weighing 11,340 gm [36]. Direct pressure on nerve roots and ischemia of neural elements due to uterine pressure on aorta and vena cava when lying on the back may result in back pain with radiation to the legs [8].

Herniated intervertebral disc disease: The approximate frequency of herniated disc disease (HDD) as a cause of low back pain during pregnancy or in the postpartum period has been estimated at 1 for 10,000 pregnancies with unilateral sciatica in 41% and bilateral sciatica in 21% [102, 116]. MRI without the use of gadolinium chelates now allows detailed evaluation of HDD without exposure of the fetus to the potential negative effects of ionising radiation [65, 104]. Abnormal disk encountered in asymptomatic pregnant women as well as the high prevalence of anatomic abnormalities discovered in asymptomatic people highlight the importance of careful correlation of symptoms and findings at MRI [20, 92, 104, 170]. In the presence of symptomatic HDD, elective caesarean section may be the preferred route of delivery with the anticipation that increasing epidural venous pressure, which is an indirect measure of CSF pressure, could precipitate progressive neurological dysfunction [103]. However, vaginal delivery can be carried under epidural anaesthesia as the elevations in both pressures are rather a product of the reflex responses of skeletal muscles to pain than contractions of the uterine musculature itself [68, 117].

Sciatica secondary to *hyperemesis gravidarum* has been described in a 34-year-old woman who presented at 9 weeks gestation with severe left leg pain [68]. Whether this resulted in a fresh disc herniation or worsened a pre-existing disc disease is not clear. Severe vomiting can be expected to trigger sciatica in the pregnant patient.

Fractures of the sacrum due to bone deficiency are not extremely uncommon in women over 60 years of age, with no trauma identified in two-thirds of the cases [60]. Taking into consideration the shifting centre of gravity, changes in the pelvic joints during pregnancy, and

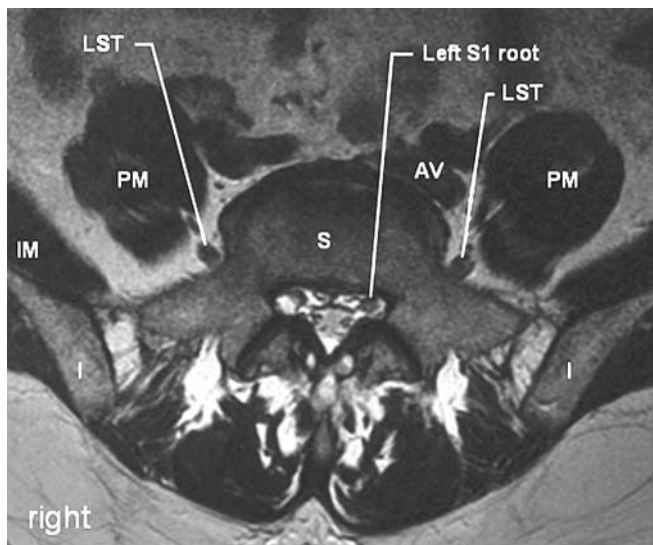


Fig.1 T2- weighted axial MRI at S1 level. AV arterio-venous bundle, I ilium, IM iliacus muscle, LST lumbosacral trunk, PM psoas major muscle, S sacrum

unaccustomed stress, we cannot exclude that some patients have sacral stress fractures such as those encountered in athletes known to produce sciatica or symptoms mimicking sciatica [114, 115]. Few cases of sacral fracture related to pregnancy have been reported in whom bone mineral density was not necessarily low [23, 74, 142, 145, 159]. Back pain, the commonest symptom related to pregnancy-associated osteoporosis, buttock pain and vertebral fracture seem to occur more often during the first pregnancy or shortly after delivery [91, 92, 94, 152]. The prognosis is generally good and recurrence rare. In some patients, the condition may be pre-existing or secondary to previous corticosteroid therapy, heparin treatment, anorexia nervosa, osteogenesis imperfecta or coeliac disease. In others, there is no identifiable cause [97, 152].

Sciatica during labour

In the *lithotomy position*, the sciatic nerve may be mechanically stretched and compressed in the gluteal region. The gluteal compartment syndrome, commonly associated with sciatic nerve compression, usually results from prolonged immobility without frequent repositioning and can be encountered with short procedure in this position [47, 141]. It has not been described during delivery. The mainstay of treatment consists of fasciotomy and debridement [82]. A pure L5 lesion with foot drop may result from direct pressure on the common peroneal nerve due to incorrectly positioned leg stirrups on the obstetrical table [2, 21, 52, 86, 109, 155, 162]. Prevention consists in positioning the knee and hip joints well flexed and avoiding extreme external rotation of the hips [6]. Treatment consists of rest, splint, or cast. The lithotomy position may also result in femoral nerve neuropraxia with weakness of quadriceps muscle and hip flexion [162]. Subsequent pregnancies should be terminated by caesarean section if axons have been crushed previously, a trial of vaginal delivery fails, or the fetus is too large [52].

The incidence of *obstetric neuropathy* during vaginal labour has been evaluated between 1 for 2,530 and 1 for 6,400 pregnancies [29, 84]. Neuropathy of the sciatic nerve can be caused by continuous pressure of the presenting part on the lumbosacral trunk as it crosses the pelvic brim during a prolonged labour [134]. Abnormal presentations (breech, occiput posterior, and occiput transverse) or craniosynostosis resulting in the inability of the fetal vertex to mould during labour may also be contributing factors [72]. One or two days after delivery, the patient presents with a burning, aching pain frequently associated with motor impairment characteristically unilateral on the side opposite the presentation of the vertex [53]. The disorder is usually a neuropraxia that can be expected to recover spontane-

ously in up to 3–4 months. Obturator, femoral, lateral femoral cutaneous nerve or pudendal plexus injury may accompany sciatic nerve injury [162]. Occasionally bilateral involvement occurs. Nerve suffering can also be caused by direct damage by the edges of the obstetric forceps during rotation procedures [12, 29, 71]. The typical patient in this case is a short woman carrying a large fetus whose labour is prolonged by cephalopelvic disproportion [53, 86].

The *piriformis syndrome* has been documented for more than 50 years and is now a well-known cause of sciatica [157]. Mechanical compression of the sciatic nerve has been reported following a piriformis haematoma after prolonged labour and a piriformis abscess after epidural anaesthesia and forceps delivery [87, 95, 100]. Sciatica associated with occasional dyspareunia secondary to sciatic nerve entrapment within a bipartite piriformis has also been described [32]. In patients presenting with sciatica without evidence of disc disease, and with prominent pain and local tenderness over the muscle exacerbated on passive hip movement in flexion, adduction, and internal rotation, one should consider piriformis muscle as a source. This can be easily confirmed by enhanced magnetic resonance, computed tomographic imaging, or electromyography. Piriformis syndrome per se may be successfully treated by surgery, physical therapy, and botulinum toxin injections [61].

The mechanisms whereby *epidural analgesia* may legitimately be associated with neurological damage may be summarised as neurotoxic, vascular, compressive, infective, and traumatic [151]. Trauma from epidural placement of the needle affects only a single nerve root in contrast to other complications which affects several roots. This can happen by placing the needle well off-centre unless there is unsuspected scoliosis. Catheters may impinge on a nerve root producing paraesthesia on insertion with symptoms which may persist occasionally for a variable time postpartum. When the epidural injection is technically difficult, the prolonged sitting position may result in sciatic nerve compression and/or ischemia in the parturient. A large volume epidural injection may precipitate an ischemic/compressive nerve root lesion in the presence of vascular malformation, disc protrusion, or stenosis of the vertebral canal [151]. The neurotoxic effect of the local anaesthetic may involve rootlets of all anaesthetised nerves and is thus bilateral [21]. In a survey in the North West Thames Region of 48,066 women delivering including 13,636 regional blocks, a single case of paraesthesia of nerve root distribution without any neurological signs could be attributed to epidural analgesia [84]. Another survey of 11,701 women who delivered in Birmingham showed that 26 women had numbness or tingling in the lower back, buttocks and leg, of whom 23 had epidural anaesthesia [112]. Effective epidural analgesia may mask the symptoms of an exacerbated pre-existing disk

prolapse or a de novo disk prolapse during labour [64]. Postpartum neurological symptoms should not be attributed to the use of epidural analgesia in labour without first ruling out other causes.

Sciatic palsy may reveal itself after *caesarean section*. The sitting position during epidural anaesthesia in thin patients, the lateral tilt position during delivery with or without severe hypotension may precipitate sciatic nerve injury after it leaves the sciatic notch [151, 163].

Sciatica secondary to pathological conditions

Leiomyomas (fibroids, myomas or fibromyomas) are the most common solid benign masses of uterine origin frequently palpated within the pelvis. They rarely appear before puberty and after menopause and are present in at least 20% of white women over the age of 30 and nearly 50% of black women [168]. Disturbance in the menstrual period with pain, often crampy in nature or labour-like, are the most striking symptoms associated with myoma. They may cause a feeling of pelvic heaviness or produce pressure symptoms on surrounding structures such as urinary frequency, stress incontinence, retention, constipation, and difficult defecation. The calcified myoma is palpable as a stony hard mass within the pelvis and is readily viewed and identified by x-ray film. Without symptoms, myomas are managed by observation as they usually regress after the menopause. Four cases of sciatica caused by direct compression of the lumbosacral trunk by the myomatous growths have been reported [1, 19, 78, 106].

The incidence of *endometriosis* varies from 5 to 20% of all women of reproductive age, more than 20% of whom present with infertility [40]. Affected teenagers and previously fertile women most commonly harbour functional hormone dependant endometrial tissue over the surface of and within the ovaries. Endometriosis can compress the sciatic nerve within the pelvis, at the sciatic notch, in the gluteal region distal to the notch, or within the sheath of the sciatic nerve [155, 167]. The commonest site is the sciatic notch where fibrosis, organised haematoma and endometrial tissue involving the muscles envelop the sciatic and sometimes the gluteal nerves [17]. Hip pain due to endometriosis in a lumbar foramen has been described [175]. Typically, patients present with pain in the hip and the buttock radiating in the leg and foot that has its onset few days before menstruation and becomes progressively more severe, subsiding 2 or 3 days to 2 weeks after cessation of menstruation; hence, the term cyclical or catamenial sciatica. As time goes on, the duration of sciatic discomfort may increase until it is constantly present with excruciating exacerbation during menses [14, 25, 26, 28, 35, 39, 44, 45, 49, 50, 55, 58, 63, 69, 73, 75, 77, 113, 124, 133, 140, 143, 144, 146, 147, 154, 156, 158, 160, 164, 167]. Diagnosis is usually late.

Vercellini et al. [166] found that two-thirds of patients with sciatic nerve endometriosis had right-side lesions. Surgical exploration of the sciatic nerve is not thought to be necessary in most cases because of the danger of a more permanent damage to the nerve [18]. Remission of symptoms during pregnancy has been reported [38]. Catamenial sciatica responds well to gonadotropin-releasing hormone analogues [18, 25, 39, 46, 58, 69, 81, 90, 124, 138, 158]. Pelvic endometriosis is accessible to laparoscopic excision.

Adenomyosis, endometrial glands and stroma found within the myometrium, is primarily a disorder of parous women over age 30 and occurs infrequently in nulliparas. The incidence varies widely (8–40%) in routine sampling of surgically removed uteri which show co-associated myomas in 36–50% of the cases [57, 105]. About 30% of myomas are asymptomatic and are discovered accidentally. The disorder manifests itself classically by progressive menstrual bleeding, increasingly painful dysmenorrhoea, and a gradually enlarging, tender uterus. The correct preoperative diagnosis is made in somewhat less than one-third of all instances. Women near the menopause may be managed for an appreciable time with analgesics alone, anticipating resolution of symptoms following cessation of menses. Hysterectomy is the only completely satisfactory treatment for adenomyosis. One case of sciatica caused by adenomyosis has been reported in a 38-year-old patient whose uterus was found in the vicinity of the right lumbosacral trunk [4].

Three cases of leg pain related to *endosalpingiosis* confirmed at laparoscopy have been described by Vilos et al. [167]. Symptoms resolved in two and remained unchanged in one in spite of prompt treatment.

Sciatica secondary to iatrogenic trauma

During *abdominal surgical procedures*, peripheral nerve injury is usually related to poor positioning of the patient, surgical dissection, or excessive pressure exerted by the surgeons [128]. In most cases, sensory or motor deficits are found as the patient emerges from anaesthesia. When a Pfannenstiel incision is chosen, the ilio-inguinal nerve may be severed or ligated, resulting in permanent numbness or burning sensation in the area of nerve distribution [88]. The sciatic nerve and the lumbosacral plexus may be injured in the control of bleeding from the hypogastric vessels [169]. The “jack-knife” position utilised in vaginal and retropubic surgery, or in diagnostic laparoscopy, is prevented by avoiding hyperextension and excessive lateral rotation of the legs and by fully supporting the back of the knees while they are suspended in stirrups. During radical hysterectomy and pelvic sidewall node dissection (Wertheim-Meigs hysterectomy) for carcinoma of the cervix, the damage

most likely to occur is to the genito-femoral and the obturator nerves. Less frequently, the femoral, peroneal, or sciatic nerves may be damaged [126].

Vaginal operations have occasionally been complicated by sciatic neuropathy, possibly because of stretching of the nerve, rather than by direct pressure [109, 136]. Two cases of gluteal artery pseudo aneurysm with sciatic nerve compression have been reported following transvaginal ultrasound-guided follicle aspiration for primary infertility [173] and transvaginal needle biopsy for endometriosis [132].

To the best of our knowledge, no neurological injuries secondary to *operative laparoscopy* have been reported yet.

During *intra-muscular injection*, the postulated mechanisms of injury to the peripheral nerves include direct needle trauma, secondary constriction by scar and direct nerve fibre damage by neurotoxic chemicals in the injected agent. The sciatic nerve is particularly vulnerable for such trauma during labour, for example [6].

Sciatica related to anatomical variations

Imperforate hymen manifests itself at puberty and adolescence often with a history of vague abdominal pain with approximately monthly exacerbation. [137]. Most cases are not diagnosed until a haematocolpos forms. Examination shows a low abdominal mass and the presence of a distended, often bluish in colour imperforate hymen. Two cases of low back pain [76, 108] and one case of sciatica secondary to haematocolpos have been reported. The accurate diagnosis in a 15-year-old girl was made after 1 year of cyclic low back pain radiating posteriorly down the legs [111]. A cruciate incision to the hymen resulted in evacuation of 1 l of altered blood under pressure and immediate resolution of her symptoms.

It has been suggested that a *retroverted uterus* may cause low back pain. A 47-year-old woman whose womb was found retroverted in direct contact with and mildly adherent to the anterior aspect of the sacroiliac joint reported sciatic pain with L5 and S1 root involvement [129]. Abdominal hysterectomy abolished the symptoms.

The *posteriorly situated colon* is a rare variant found in 1% of people, more commonly women, in which the colon extends so medially that it abuts the ventral rami leading to potential compression of these during gaseous and faecal distension [48, 149]. McPherson et al. [119] described a 42-year-old woman with 4-year history of intermittent low back and left buttock pain associated with a positive straight leg raising test whose left L4 and L5 ventral rami were adjacent to the descending colon passing posterior to the left psoas and anterior to the quadratus lumborum and iliacus muscles.

Miscellaneous causes of sciatica

Albeit major changes in their designs, *intrauterine devices* (IUD) have a high morbidity [34]. Perforation of the uterine wall has an incidence from 0.0 to 8.7/1,000 insertions and may result from technical faults during insertion, uterine contractions after insertion, and certain anatomic abnormalities which may be considered as relative contraindications [34]. Fundal perforation at the time of insertion is accompanied with pain and bleeding. Later, it may be "silent" and recognised on a subsequent follow-up when IUD is found displaced, the string absent or the patient obviously pregnant. IUD migration complicated by ileosigmoid fistula, small and large bowel perforation, appendicitis, peritonitis, rupture of the uterus in subsequent pregnancy, perforation of the bladder and obstructive nephropathy has been reported. Review of the lumbosacral roentgenograms of a 25-year-old woman who presented with right-sided sciatica revealed an IUD in the vicinity of the right psoas muscle [56]. Symptoms improved immediately after its removal by laparoscopy from the posterior cul-de-sac where it was found anterior to the lumbosacral nerve roots.

Tubeoovarian abscess (TOA) is an end-stage process of acute pelvic inflammatory disease caused by microorganisms colonising the endocervix ascending to the endometrium and the fallopian tubes. Traditionally, TOA is diagnosed when a patient with pelvic pain and fever presents with a pelvic mass. One case of sciatica secondary to a TOA has been reported in a 25-year-old patient presenting with low grade fever and severe right sciatic pain after a fall 3 weeks before admission [7]. She responded well to intravenous anti-microbial therapy as do approximately 75% of women with TOA.

Osteophytes at the sacroiliac joints secondary to the stress produced by the mobility of these joints to facilitate parturition are usually found at the anteroinferior portion of the joint [154]. Three patients have been reported to present restricted straight leg raising tests with tenderness at the level of the sciatic notch [101]. One had evidence of L5 root suffering, another had S1 root suffering while in the third, neurological examination was normal. They responded to local anaesthetic infiltration but two needed further surgical removal of the osteophyte.

Extra-spinal involvement of the sciatic nerve by *primary malignant tumours* or *secondary metastasis* has been reported at the level of the sacroiliac joint by bone metastasis from a breast cancer and in the region of the greater sciatic foramen by endometrial carcinoma [27, 33].

Discussion

Disc prolapse is by far the most popular and common cause of sciatica [2, 24, 51, 122, 123, 139]. The annual incidence is about 5% per year in 20–40-year-olds with

Table 1 Gynaecological and obstetrical conditions reported to produce sciatica and symptoms mimicking sciatica

Causes	Presentation	Delay until diagnosis	<i>n</i>
Endometriosis	Unilateral or bilateral leg or buttock pain, sciatica with or without low back pain	4 months–15 years	66
Herniated disc during pregnancy/post-partum	Unilateral or bilateral sciatic pain	Immediate–3 months	19
Obstetric neuropathy during delivery (with and without epidural analgesia)	Unilateral pain, paraesthesia	Immediate	13
Fracture of the sacrum during pregnancy/post-partum	Unilateral or bilateral leg or buttock pain	Immediate–3 months	5
Fibroids	Unilateral sciatic pain and low back pain	Immediate–4.5 years	4
Endosalpingiosis	Unilateral leg pain	Immediate	3
Osteophytes at the sacroiliac joints	Unilateral sciatic pain	12–24 months	3
Bone metastasis	Unilateral sciatic pain	12 months	2
Gluteal artery pseudo aneurism after vaginal procedures	Unilateral sciatic pain	Immediate–25 days	2
Piriformis abscess (one case after delivery)	Unilateral sciatic pain	Immediate	2
Adenomyosis	Unilateral sciatic pain	12 months	1
Imperforate hymen	Bilateral sciatic pain and low back pain	12 months	1
Impingement of sciatic nerve in bipartite piriformis	Occasional dyspareunia, unilateral sciatica after a fall	3 years	1
Intrauterine device migration	Unilateral sciatic pain and low back pain	14 months	1
Piriformis haematoma during delivery	Unilateral sciatic pain	Immediate	1
Posteriorly situated colon	Intermittent back pain radiating to buttock, perineum	4 years	1
Retroverted uterus	Unilateral lower limb distal weakness	Not mentioned	1
Tubeoovarian abscess	Unilateral sciatic pain and low back pain	3 weeks	1

Immediate refers to one week or less.

lesions occurring most often at L4-L5 and L5-S1 segments [79]. Newer imaging tools and refinements of electrophysiological studies have identified many other lesions as potential causes: hip diseases [67, 107, 110, 150] pelvic diseases [3, 13, 31, 83, 120, 148, 172] spinal canal disease [9, 15, 54, 62, 70, 89, 125, 130, 131, 135] central nervous system tumours [5, 16, 176] vascular malformation and disease [42, 43, 85, 121] and infectious disease [93, 161].

Differentiating sciatica due to lumbar disc disease from those due to other pathologic conditions can be a difficult diagnostic dilemma. In the female patient, when imaging of the spinal canal is equivocal, CT or MRI evaluation of the greater sciatic foramen can be helpful [17, 32, 33]. Direct compression of ventral rami or the lumbosacral plexus by an enlarged uterus may result in sciatica with or without neurological deficit. The cyclic nature of pain makes the diagnosis of catamenial sciatica highly probable during the child-bearing age and imperforate hymen with haematocolpos in the teenage girl [111]. Anatomical variations and medical interventions may unusually present with sciatica.

The main presenting symptom of female sex related sciatica was in this review L3, L5, or S1 radicular pain. Lumbosacral plexopathy pain, diffuse leg pain and hip pain with or without neurological deficit were also reported (Table 1).

In the largest endometriosis group, diagnosis was made correctly on clinical basis in eight patients (12%)

as the history of endometriosis and/or the cyclic pattern of symptoms were suggestive [46, 58, 75, 81, 90]. In the others, diagnosis was delayed in average 3.8 years (1 month–15 years) [80]. MRI suggested the diagnosis in three cases [45, 81, 174]. During pregnancy, labour, and the post-partum, diagnosis was either immediate within few days when sciatica was related to a herniated disc, or was delayed with sacral stress fractures up to 4.5 months [159]. For the other cases, diagnosis was made within 1 year except for one case with sacroiliac osteophytosis, which was diagnosed 2 years after the onset of symptoms [103]. Intervertebral disk disease was suspected in 49 patients (38.5%) [1, 2, 4, 7, 10, 14, 17, 18, 27, 28, 32, 35, 45, 50, 63, 69, 77, 80, 98, 101, 111, 113, 124, 129, 133, 138, 143, 146, 147, 152, 156, 160, 174, 175] and led to surgical procedures without any benefit in five patients [10, 18, 77, 80, 143, 164]. Other tentative diagnoses were low back pain and/or lumbar arthritis, abdominal adhesions, peroneal palsy, piriformis syndrome, uterine fibroid, lumbosacral radiculopathy and local buttock problem. Psychiatric illness was suspected during the course of the illness in three patients [80, 98, 164]. Some patients had one or more myelogram, CT, MRI, EMG, or CSF analysis and even barium enema studies. Some were seen by several specialists before the final diagnosis was made, Zangger's case being the most illustrative as the patient was seen by 17 physicians before endometriosis was diagnosed [175]. Hysterectomy abolished symptoms in five patients (4%) [1, 4, 19, 106, 129].

The cases reported by Baker et al. [10], Björnsson [18], Hibbard et al. [80], Kohorn [98], Laman et al. [106] and Vaisberg [164] are illustrative of the difficulty one may face before correct diagnosis is made in the female patient presenting with leg pain.

Conclusion

In any case of sciatica in a female patient, it seems cogent to the diagnosis that a detailed menstrual history be taken, bearing in mind the possibility that an endometrial implant on or nearby the sciatic nerve, a heavy and/or voluminous uterus or other gynaecological diseases may result in recurring leg pain, weakness, and/or sensory loss. The cyclic pattern of sciatic pain is highly

suggestive of endometriosis and should be searched for systematically, and considered in the differential diagnosis.

The search for a gynaecological/obstetric aetiology for pain should be considered even though imaging techniques reveal either a herniated disc or other pathologic conditions of the spine which correlate with the symptoms [164].

In patients presenting with sciatica without evidence of disc disease, the evaluation should not be considered complete without scanning the course of the nerve through the greater sciatic foramen. With prominent pain on passive hip movement, one should consider pelvic muscle disease easily confirmed by enhanced magnetic resonance or compute tomographic imaging.

References

- Acar B, Kadanali S (1993) Rare gynecological condition causing sciatic pain. *Int J Gynaecol Obstet* 42:50–51
- Adams RD, Victor M (1993) Pain in the back, neck, and extremities. In: Adams RD, Victor M (eds) *Principles of neurology*. McGraw-Hill, New York, pp 171–196
- Akhaddar A, Gourinda H, el Alami Z, el Mahdi T, Miri A (1999) Hydatid cyst of the sacrum. Report of a case. *Rev Rhum Engl Ed* 66(5):289–291
- Al-Khodairy AT, Gerber BE, Praz G (1995) Adenomyosis—an unusual cause of sciatic pain. *Eur Spine J* 4:317–319
- Allanore Y, Hilliquin P, Zuber M, Renoux M, Menkes CJ, Kahan A (1999) A leptomeningeal metastasis revealed by sciatica. *Rev Rhum Engl Ed* 66(4):232–234
- Aminoff MJ (1989) Pregnancy and disorders of the nervous system. In: Aminoff MJ (ed) *Neurology and general medicine; the neurological aspects of medical disorders*. Churchill Livingstone, New York, pp 487–503
- Andrews DW, Friedman NB, Heier L, Erickson A, Lavyne M H (1987) Tuboovarian abscess presenting as sciatic pain; case report. *Neurosurgery* 21(1):100–103
- Ashkan K, Casey ATH, Powell M, Crockard HA (1998) Back pain during pregnancy and after childbirth: an unusual cause not to miss. *J R Soc Med* 91:88–90
- Avimadje AM, Goupille P, Zerkak D, Begnard G, Brunais-Besse J, Valat JP (2000) Monostotic fibrous dysplasia of the lumbar spine. *Joint Bone Spine* 67(1):65–70
- Baker GS, Parsons WR, Welch JS (1966) Endometriosis within the sheath of the sciatic nerve: report of two patients with progressive paralysis. *J Neurosurg* 25:652–655
- Beaton LE, Anson BJ (1938) The sciatic nerve and the piriformis muscle: their interrelationship, a possible cause of coccygodynia. *J Bone Joint Surg* 20(3):686–688
- Beazley JM (1986) Maternal injuries and complications. In: Whitfield CR (ed) *Dewhurst's textbook of obstetrics and gynaecology for postgraduates*. Blackwell, Oxford, pp 417–427
- Benyahya E, Etaouil N, Janani S, Bennis R, Tarfeh M, Louhalia S, Mkinsi O (1997) Sciatica as the first manifestation of a leiomyosarcoma of the buttock. *Rev Rhum Engl Ed* 64(2):135–137
- Bergqvist A, Bergqvist D, Lindholm K, Linell F (1987) Endometriosis in the uterosacral ligament giving orthopedic symptoms through compression of the sciatic nerve and surgically treated via an extraperitoneal approach keeping the pelvic organs intact, case report. *Acta Obstet Gynecol Scand* 66:93–94
- Bickels J, Kahanovitz N, Rubert CK, Henshaw RM, Moss DP, Meller I, Malawer MM (1999) Extraspinal bone and soft-tissue tumors as a cause of sciatica. Clinical diagnosis and recommendations analysis of 32 cases. *Spine* 24(15):1611–1616
- Bielsa C, André M, Schmidt J, Geoget AM, Chazal J, Dordain G, Aumaitre O (1997) Une sciatique paralysante d'origine centrale. *Rev Méd Interne* 18:730–731
- Binkovitz LA, King BF, Ehman RL (1991) Sciatic endometriosis: MR appearance. *J Comput Assist Tomogr* 15(3):508–510
- Björnsson OG (1976) Cyclic sciatica of endometriosis—case report. *Acta Chir Scand* 142:415–416
- Bodack MP, Cole JC, Nagler W (1999) Sciatic neuropathy secondary to a uterine fibroid: a case report. *Am J Phys Med Rehabil* 78(2):157–159
- Boden SD, Davis DO, Dina TS, Patronas NJ, Wiesel SW (1990) Abnormal magnetic resonance scans of the lumbar spine in asymptomatic patients. *J Bone Joint Surg Am* 72A:403–408
- Bonica JJ (1990) Pelvic and perineal pain caused by other disorders. In: Bonica JJ (ed) *The management of pain*. Lea & Febiger, Philadelphia, pp 1383–1394
- Bradley WG (1991) Low back and lower limb pain. In: Bradley WG, Daroff RB, Fenichel GM, Marsden CD (eds) *Neurology in clinical practice; Principles of diagnosis and management*. Butterworths, Stoneham, pp 405–414
- Breuil V, Brocq O, Euller-Ziegler L, Grimaud A (1997) Insufficiency fracture of the sacrum revealing a pregnancy associated osteoporosis. First case report. *Ann Rheum Dis* 56(4):278–279
- Buruma OJS, Maat GJR (1987) Lumbosacral plexus lesions. In: Vinken PJ, Bruyn GW, Klawans HL (eds) *Handbook of clinical neurology*. Elsevier, Amsterdam, (51) pp 157–170

25. Calzada-Sierra DJ, Fermin-Hernandez E, Vasallo-Prieto R, Gomez-Fernandez L, Santana de la Fe A (1999) Ciática ciclica bilateral por endometriosis. A proposito de un caso. *Rev Neurol* 29(1):34-36
26. Caprioglio A (1953) Sopra due casi di endometriosi. *Minerva Ginecol* 5:532-535
27. Carey I, Balague F, Waldburger M (1995) Pseudosciatique d'origine néoplasique: à propos d'un cas inhabituel. *Schweiz Rundsch Med Prax* 84(7):197-199
28. Carta F, Guiducci G, Fulcheri E, Bernucci C, Rivano C (1992) Radicular compression by extradural spinal endometriosis, case report. *Acta Neurochir* 114:68-71
29. Cartledge NEF (1990) Maladies neurologiques. In: Barron WM, Lindheimer MD, Davison JD (eds) *Médecine de la femme enceinte*. Flammarion, Paris, pp 514-539
30. Chad DA (1991) Disorders of roots and plexuses. In: Bradley WG, Daroff RB, Fenichel GM, Marsden CD (eds) *Neurology in clinical practice: Principles of diagnosis and management*. Butterworths, Stoneham, pp 1793-1818
31. Chatagnier H, Onimus M (1998) Sciatique L5 par compression du tronc lombo-sacré d'origine osseuse au niveau de la sacro-iliaque. Traitement par voie antéro-latérale sous péritonéale. *Rev Chir Orthop Reparatrice Appar Mot* 84(4):377-380
32. Chen WS (1994) Bipartite piriformis muscle: an unusual cause of sciatic nerve entrapment. *Pain* 58(2):269-272
33. Cohen BA, Lanzieri CF, Mendelson DS, Sacher M, Hermann G, Train JS, Rabinowitz JG (1986) CT evaluation of the greater sciatic foramen in patients with sciatica. *AJNR Am J Neuroradiol* 7(2):337-342
34. Connell EB (1990) Intrauterine devices. In: Kase NG, Weingold AB, Gershenson DM (eds) *Principles and practice of clinical gynecology*. Churchill Livingstone, New York, pp 1021-1042
35. Cottier JP, Descamps P, Sonier CB, Rosset P (1995) Sciatic endometriosis MR evaluation. *AJNR Am J Neuroradiol* 16(7):1399-1401
36. Cunningham FG, MacDonald PC, Leveno KJ, Gant N, Gilstrap LC (1993) The morphological and functional development of the foetus. In: Cunningham FG, MacDonald PC, Leveno KJ, Gant N, Gilstrap LC (eds) *Williams obstetrics*. Prentice-Hall, New Jersey, pp 165-207
37. Cunningham FG, MacDonald PC, Leveno KJ, Gant NF, Gilstrap LC (1993) Maternal adaptations to pregnancy. In: Cunningham FG, MacDonald PC, Leveno KJ, Gant NF, Gilstrap LC (eds) *Williams obstetrics*. Prentice-Hall, New Jersey, pp 209-246
38. Dagnelie MJ (1947) Lombo-sciatalgie et endocrinologie. Contribution à l'étude des endométriomes hétérotopiques. *Ann Endocrinol (Paris)* 8:26-31
39. DeCesare SL, Yeko TR (1995) Sciatic nerve endometriosis treated with a gonadotropin releasing hormone agonist. A case report. *J Reprod Med* 40(3):226-228
40. DeCherney AH (1990) Endometriosis. In: Kase NG, Weingold AB, Gershenson DM (eds) *Principles and practice of clinical gynecology*. Churchill Livingstone, New York, pp 459-464
41. Dee R (1989) Degenerative diseases and disc disorders of the lumbar spine. In: Dee R, Mango E, Hurst LC (eds) *Principles of orthopaedic practice*. McGraw-Hill, New York, pp 997-1034
42. Demaerel P, Petrè C, Wilms G, Plets C (1999) Sciatica caused by a dilated epidural vein: MR findings. *Eur Radiol* 9(1):113-114
43. Demeulenaere A, Spelle L, Lafitte F, Brunet E, Chiras J (1999) Les malformations vasculaires vertebro-épidurales lombo-sacrées. Une cause inhabituelle de lombo-sciatique. *J Neuroradiol* 26(4):225-235
44. Denton RO, Sherrill JD (1955) Sciatic syndrome due to endometriosis of sciatic nerve. *South Med J* 48:1027-1030
45. Descamps Ph, Cottier JP, Barre I, Rosset Ph, Laffont J, Lansac J, Body G (1995) Endometriosis of the sciatic nerve: case report demonstrating the value of MR imaging. *Eur J Obstet Gynecol Reprod Biol* 58(2):199-202
46. Dhôte R, Tudoret L, Bachmeyer C, Legmann P, Christoforov B (1996) Cyclic sciatica. A manifestation of compression of the sciatic nerve by endometriosis. A case report. *Spine* 21(19):2277-2279
47. Dimachkie MM, Ohanian S, Groves MD, Vriesendorp FJ (2000) Peripheral nerve injury after brief lithotomy for transurethral collagen injection. *Urology* 56(4):669
48. Dixon AK, Henderson PI, Oliver JL, Matthewson MH (1993) Posteriorly situated retroperitoneal colon: a study using CT and MRI. *Clin Anat* 6:269-274
49. Do Amaral Ferreira C (1952) Endometrioma da região sacro-coccigea. *An Bras Ginecol* 33:373-376
50. Dognon L, Himmi A, Avigdor S, Descamps P, Rosset P, Cottier JP, Fignon A, Lansac J, Body G (1994) Sciatalgie cataméniale par endométriome du nerf sciatique. Revue de la littérature, a propos d'un cas. *J Gynecol Obstet Biol Reprod (Paris)* 23(4):386-390
51. Donaghy M (1993) Disorders of peripheral nerves. In: Walton J (eds) *Brain's diseases of the nervous system*. Oxford University, Oxford, pp 555-624
52. Donaldson JO (1992) Neurologic complications of pregnancy. In: Asbury AK, McKhann GM, McDonald WI (eds) *Diseases of the nervous system: clinical neurobiology*. Saunders, Philadelphia, pp 1545-1551
53. Donaldson JO (1998) Neurologic complications. In: Burrow GN, Ferris TF (eds) *Medical complications during pregnancy*. Saunders, Philadelphia, pp 485-498
54. Dullerud R, Server A, Berg-Johnsen J (2003) MR imaging of ventriculus terminalis of the conus medullaris. A report of two operated patients and a review of the literature. *Acta Radiol* 44(4):444-446
55. Duun S (1984) Cyklisk ischias. En manifestation af endometriose. *Ugeskr Laeger* 146(12):886-887
56. Elmer RM (1978) Sciatica caused by an intrauterine device after silent uterine perforation. *J Bone Joint Surg* 60A(2):265-266
57. Entman SS (1988) Uterine leiomyoma and adenomyosis. In: Jones HW III, Wentz AC, Burnet LS (eds) *Novak's textbook of gynecology*. Williams & Wilkins, Baltimore, pp 443-454
58. Fedele L, Bianchi S, Raffaelli R, Zanonato G, Zanette G (1999) Phantom endometriosis of the sciatic nerve. *Fertil Steril* 72:727-729
59. Ferreira do Amaral C (1952) Endometrioma da região sacrococcigea. *An Bras Ginec* 33:373-376
60. Finiels H, Finiels PJ, Jacquot JM, Strubel D (1997) Fractures of the sacrum caused by bone insufficiency. Meta-analysis of 508 cases. *Presse Med* 26(33):1568-1573
61. Fishman LM, Anderson C, Rosner B (2002) BOTOX and physical therapy in the treatment of piriformis syndrome. *Am J Phys Med Rehabil* 81(12):936-942
62. Fiumara E, Scarabino T, Guglielmi G, Bisceglia M, D'Angelo V (1999) Osteochondroma of the L-5 vertebra: a rare cause of sciatic pain. Case report. *J Neurosurg* 91(2 Suppl):219-222
63. Forrest JS, Brooks DL (1972) Cyclic sciatica of endometriosis. *JAMA* 222(9):1177-1178

64. Forster MR, Nimmo GR, Brown AG (1996) Prolapsed intervertebral disc after epidural analgesia in labour. *Anaesthesia* 51(8):773-775
65. Forstner R, Kalbhen CL, Filly RA, Hricak H (1996) Abdominopelvic MR imaging in the non obstetric evaluation of pregnant patients. *AJR Am J Roentgenol* 166:1139-1144
66. Fournie A (1990) A propos des signes cliniques de la névralgie sciatique par hernie discale. In: Simon L, Hérisson Ch, Privat J.-M, Bouvier J.-P, Fedou P (eds) *La hernie discale lombaire*. Masson, Paris, pp 15-19
67. Garcia S, Cofan F, Combalia A, Casas A, Campistol JM, Oppenheimer F (1999) Compresion del nervio ciatico en la calcinosis tumoral uremica. *Neurologia* 14(2):86-89
68. Garmel SH, Guzelian GA, D'Alton JG, D'Alton ME (1997) Lumbar disk disease in pregnancy. *Obstet Gynecol* 89:821-822
69. Gaujoux J, Serratrice G (1972) Une sciatique cataméniale. *Mars Med* 109(9):575-577
70. Giraud F, Fontana A, Mallet J, Fischer LP, Meunier PJ (2001) Sciatica caused by epidural gas. Four case reports. *Joint Bone Spine* 68(5):434-437
71. Goldblatt D, Monoplegia (1991) In: Bradley WG, Daroff RB, Fenichel GM, Marsden CD (eds) *Neurology in clinical practice; Principles of diagnosis and management*. Butterworths, Stoneham, pp 239-248
72. Gonik B, Stringer CA, Cotton DB, Held B (1984) Intrapartum maternal lumbosacral plexopathy. *Obstet Gynecol* 63(3 Suppl):455-465
73. Granberry WM, Henderson ED, Miller RH, Faber JE, Dockerty MB (1959) Endometriosis of sciatic nerve without evidence of pelvic endometriosis. Report of a case. *Minn Med* 42:1794-1797
74. Grimaud A, Oddo F, Thibaud I, Brocq O, Euler-Ziegler L (1997) Fracture du sacrum par insuffisance osseuse chez une femme enceinte. *J Radiol* 78(1):511-512
75. Guiot G, Levy J, Auquier L, Comoy C (1965) Sciaticque par endométriose (La sciatique cataméniale). *Presse Med* 24:1397-1398
76. Harrison CS (1991) Hematocolpos as a cause of low-back-pain. A case report. *Spine* 16:985-986
77. Head HB, Welch JS, Mussey E, Espinosa RE (1962) Cyclic sciatica. *JAMA* 180(7):521-524
78. Heffernan LPM, Fraser RC, Purdy RA (1980) L-5 Radiculopathy secondary to a uterine leiomyoma in a primigravid patient. *Am J Obstet Gynecol* 138(4):460-461
79. Hertling D (1990) The lumbar spine. In: Hertling D, Kessler RM (eds) *Management of common musculoskeletal disorders; physical therapy principles and methods*. Lippincott, Philadelphia, pp 542-627
80. Hibbard J, Schreiber JR (1984) Foot-drop due to sciatic nerve endometriosis. *Am J Obstet Gynecol* 149(7):800-801
81. Hickey NA, Murphy JP, Bloom C, Hamilton P (1999) Magnetic resonance imaging of endometriosis of the piriformis muscle causing sciatica: case report. *Can Assoc Radiol J* 50(1):33-36
82. Hill SL, Bianchi J (1997) The gluteal compartment syndrome. *Am Surg* 63(9):823-826
83. Hodge JC, Bessette B (1999) The incidence of sacroiliac joint disease in patients with low-back pain. *Can Assoc Radiol J* 50(5):321-323
84. Holdcroft A, Gibberd FB, Hargrove RL, Hawkins DF, Dellaportas CI (1995) Neurological complications associated with pregnancy. *Br J Anaesth* 75:522-526
85. Holtzman RN, Brisson PM, Pearl RE, Gruber ML (1999) Lobular capillary hemangioma of the cauda equina. Case report. *J Neurosurg* 90(4):239-241
86. Hopkins A (1989) Neurological disorders. In: de Swiet M (eds) *Medical disorders in obstetric practice*. Blackwell, Oxford, pp 731-774
87. Hu MTM, Shaw CE, Evans S, Britton TC (1998) Acute sciatica with an infective cause. *J R Soc Med* 91:87-88
88. Hunt RB (1992) Complications of infertility surgery. In: Hunt RB (ed) *Atlas of female infertility surgery*. Mosby, St. Louis, pp 485-495
89. Ito T, Homma T, Uchiyama S (1999) Sciatica caused by cervical and thoracic spinal cord compression. *Spine* 24(12):1265-1267
90. Jelk W, Estape R (1995) Zyklische Ischialgie und extrauterine Endometriose. *Schweiz Rundsch Med Prax* 84(46):1349-1355
91. Jensen JE, Mortensen G (2000) Graviditetsinduceret osteoporose. *Ugeskr Laeger* 162(27):3865-3866
92. Jensen MC, Brant-Zawadzki MN, Obuchowski N, Modic MT, Malkasian D, Ross JS (1994) Magnetic resonance imaging of the lumbar spine in people without back pain. *N Engl J Med* 331:69-73
93. Kane D, McCarthy DJ (1997) Tropical pyomyositis presenting as sciatica in Wicklow. *Ir Med J* 90(4):155
94. Khovichunkit W, Epstein S (1996) Osteoporosis in pregnancy. *Osteoporos Int* 6(5):345-354
95. Kinahan AM, Douglas MJ (1995) Piriformis pyomyositis mimicking epidural abscess in a parturient. *Can J Anaesth* 42(3):240-245
96. King TT (1991) Effects of degenerative disease of the spinal column on the nervous system. In: Swash M, Oxbury J (eds) *Clinical neurology*. Churchill Livingstone, London, pp 536-561
97. Kohlmeier L, Marcus R (1995) Calcium disorders in pregnancy. *Endocrinol Metab Clin North Am* 24:15-39
98. Kohorn EI (1963) Neurological complications of endometriosis. *Proc R Soc Med* 56:874-875
99. Kristiansson P, Svärdsudd K, Von Schultz B (1996) Back pain during pregnancy: a prospective study. *Spine* 21:702-709
100. Ku A, Kern H, Lachman E, Nagler W (1995) Sciatic nerve impingement from piriformis hematoma due to prolonged labour. *Muscle Nerve* 18(7):789-790
101. Kumar B, Sriram KG, George C (2002) Osteophyte at the sacroiliac joint as a cause of sciatica: a report of four cases. *J Orthop Surg (Hong Kong)* 10(1):73-76
102. LaBan MM, Perrin JCS, Latimer FR (1983) Pregnancy and the herniated lumbar disc. *Spine* 64:319-321
103. LaBan MM, Rapp NS, von Oeyen P, Meerschaert JR (1995) The lumbar herniated disk of pregnancy: A report of six cases identified by magnetic resonance imaging. *Arch Phys Med Rehabil* 76:476-479
104. LaBan MM, Viola S, Williams DA, Wang A (1995) Magnetic resonance of the lumbar herniated disc in pregnancy. *Am J Phys Med Rehabil* 74:59-61
105. Lacey CG (1991) Benign disorders of the uterine corpus. In: Pernoll ML (eds) *Current obstetrics and gynecologic diagnosis and treatment*. Appleton, Connecticut, pp 456-479
106. Laman DM, Endtz LJ, van Well-Krouwel HJ, Gerretsen G (1985) A rare cause of lumbosacral plexus neuropathy. *Clin Neurol Neurosurg* 87(1):47-49
107. Lee YY, Wen-Wei Hsu R, Huang TJ, Hsueh S, Wang JY (2002) Metastatic meningioma in the sacrum: a case report. *Spine* 27(4):E100-E103
108. Letts M, Haasbeek J (1990) Hematocolpos as a cause of back pain in premenarchal adolescents. *J Pediatr Orthop* 10:731-732
109. Liveson JA (1991) Localized processes. In: Liveson JA (ed) *Peripheral neurology; case studies in electrodiagnosis*. FA Davis, Philadelphia, pp 19-59
110. Loeser JD (1990) Pain of neurologic origin in the hips and lower extremities. In: Bonica JJ (ed) *The management of pain*. Lea & Febiger, Philadelphia, pp 1515-1529

111. London NJ, Sefton GK (1996) Hematomocolpos. An unusual cause of sciatica in an adolescent girl. *Spine* 21(11):1381–1382
112. MacArthur C, Lewis M, Knox EG (1992) Investigation of long term problems after obstetric epidural anaesthesia. *BMJ* 304:1279–1282
113. Macek C (1983) Neurological deficits, back pain tied to endometriosis. *JAMA* 249(6):686
114. Major NM, Helms CA (1997) Pelvic stress injuries: the relationship between osteitis pubis (symphysis pubis stress injury) and sacroiliac abnormalities in athletes. *Skeletal Radiol* 26(12):711–717
115. Major NM, Helms CA (2000) Sacral stress fractures in long-distance runners. *Am J Roentgenol* 174(3):727–729
116. Mantle MJ, Greenwood RM, Currey HL (1977) Backache in pregnancy. *Rheumatol Rehabil* 16:95–101
117. Marx GF, Oka Y, Orkin LR (1962) Cerebrospinal fluid pressures during labour. *Am J Obstet Gynecol* 84:213–219
118. McCarthy SM, Stark DD, Filly RA, Callen PW, Hricak H, Higgins CB (1985) Obstetrical magnetic resonance imaging: maternal anatomy. *Radiology* 154:421–425
119. McPherson SJ, Everson DH, Jenner JR, Dixon AK (1997) Abnormal colonic position as an explanation for radiculopathy. *Lancet* 349(9067):1773
120. Meknas K, Christensen A, Johansen O (2003) The internal obturator muscle may cause sciatic pain. *Pain* 104(1–2):375–380
121. Merlo IM, Poloni TE, Alfonsi E, Messina AL, Ceroni M (1997) Sciatic pain in a young sportsman. *Lancet* 349:846
122. Mignucci LA, Bell GR (1992) Differential diagnosis of sciatica. In: Rothman RH, Simeone FA (eds) *The Spine*. Saunders, Philadelphia, pp 107
123. Misoul C (1989) Nerve injuries and entrapment syndromes of the lower extremity. In: Dee R, Mango E, Hurst LC (eds) *Principles of orthopaedic practice*. McGraw-Hill, New York, pp 1420–1430
124. Moeser P, Donofrio PD, Karstaedt N, Bechtold R, Greiss FC Jr (1990) MRI findings of sciatic endometriosis. *Clin Imaging* 14(1):64–66
125. Moller H, Sundin A, Hedlund R (2000) Symptoms, signs, and functional disability in spondylolisthesis. *Spine* 25(6):683–689
126. Monaghan JM (1987) Radical hysterectomy and pelvic node dissection (Wertheim–Meigs hysterectomy). In: Dudley H, Carter DC, Russell RCG (eds) *Rob & Smith's operative surgery*. Butterworths, London, pp 183–192
127. Moore KL (1985) The perineum and pelvis. In: Moore KL (eds) *Clinically oriented anatomy*. Williams & Wilkins, Baltimore, pp 298–395
128. Munro MG (1996) Gynecologic endoscopy. In: Berek JS, Adashi EY, Hildard PA (eds) *Novak's gynecology*. Williams & Wilkins, Baltimore, pp 677–725
129. Murata Y, Takahashi K, Murakami M, Moriya H (2001) An unusual cause of sciatic pain. *J Bone Joint Surg Br* 83(1):112–113
130. O'Connor D, Maskery N, Griffiths WE (1998) Pseudomeningocele nerve root entrapment after lumbar discectomy. *Spine* 23(13):1501–1502
131. Paci G, Vandergugten M (1997) Kyste synovial du rachis lombaire. *J Belge Radiol* 80(2):73–74
132. Papadopoulos SM, McGillicuddy JE, Messina LM (1989) Pseudoaneurysm of the inferior gluteal artery presenting as sciatic nerve compression. *Neurosurgery* 24(6):926–928
133. Papapietro N, Gulino G, Zobel BB, Di Martino A, Denaro V (2002) Cyclic sciatica related to an extrapelvic endometriosis of the sciatic nerve: new concepts in surgical therapy. *J Spinal Disord Tech* 15(5):436–439
134. Pryse-Phillips W, Murray TJ (1986) Weakness In: Pryse-Phillips W, Murray TJ (eds) *Essential neurology*. Medical Examination Publishing Library, New York, pp 338–345
135. el Quessar A, Chakir N, el Hassani MR, Jiddane M, Boukhrissi N (1998) Exostose vertébrale et compression médullaire. *J Neuroradiol* 25(3):233–236
136. Raz S (1992) Complications of vaginal surgery. In: Raz S (eds) *Atlas of transvaginal surgery*. Saunders, Philadelphia, pp 37–47
137. Rebar RW (1996) Puberty. In: Berek JS, Adashi EY, Hildard PA (eds) *Novak's gynecology*. Williams & Wilkins, Baltimore, pp 771–807
138. Reis J (1997) Sciatalgie et scapalgie révélatrices d'endométriose. *Rev Neurol (Paris)* 143(4):282
139. Revel M, Amor B (1992) Les sciatiques en dehors de la hernie discale. *Rev Prat* 42(5):549–553
140. Richards BJ, Gillett WR, Pollock M (1991) Reversal of foot drop in sciatic nerve endometriosis. *J Neurol Neurosurg Psychiatry* 54(10):935–936
141. Roth JS, Newman EC (2002) Gluteal compartment syndrome and sciatica after bone marrow biopsy: a case report and review of the literature. *Am Surg* 68(9):7921–794
142. Rousière M, Kahan A, Job-Deslandre C (2001) Postpartal sacral fracture without osteoporosis. *Joint Bone Spine* 68(1):71–73
143. Salazar-Gruesso E, Roos R (1986) Sciatic endometriosis: a treatable sensorimotor mononeuropathy. *Neurology* 36(10):1360–1363
144. Schlicke CP (1946) Ectopic endometrial tissue in the thigh. *JAMA* 132(8):445–446
145. Schmid L, Pfirrmann C, Hess T, Schlumpf U (1999) Bilateral fracture of the sacrum associated with pregnancy: a case report. *Osteoporos Int* 10(1):91–93
146. Schoenenberger AW, Steiner P, Debatin JF, Pfammatter T, Kacl GM (1996) Funktionen an einem offenen, interventionellen MR-Gerat. Veranschaulichung anhand eines Fallbeispiels. *Radiologe* 36(9):705–708
147. Schroth G, Becker M, Nirkkko A (1995) Endometriose des Nervus ischiadicus. *Rofo* 163(2):186–189
148. Servant CTJ (1998) An unusual cause of sciatica. A case report. *Spine* 23(19):2134–2136
149. Sherman JL, Hopper KD, Green AJ, Johns TT (1985) The retrorenal colon on computed tomography: a normal variant. *J Comput Assist Tomogr* 9:339–341
150. Sherman PM, Matchette MW, Sanders TG, Parsons TW (2003) Acetabular paralabral cyst: an uncommon cause of sciatica. *Skeletal Radiol* 32(2):90–94
151. Silva M, Mallison C, Reynolds F (1996) Sciatic nerve palsy following childbirth. *Anaesthesia* 51:1144–1148
152. Smith R, Phillips AJ (1998) Osteoporosis during pregnancy and its management. *Scand J Rheumatol Suppl* 107:66–67
153. Smith R, Athanasou NA, Ostlere SJ, Vipond SE (1995) Pregnancy-associated osteoporosis. *QJM* 88(12):865–878
154. Stewart TD (1984) Pathologic changes in aging sacroiliac joints. A study of dissecting-room skeletons. *Clin Orthop* 183:188–196
155. Stewart JD (1993) The cauda equina and the lumbar and sacral nerve roots and spinal nerves. In: Stewart JD (eds) *Focal peripheral neuropathies*. Raven, New York, pp 261–319
156. Stewart J, Murphy G, Wee R (1981) Sciatic nerve palsy due to endometriosis. *Can J Neurol Sci* 8:202
157. Synek VM (1987) The piriformis syndrome: review and case presentation. *Clin Exp Neurol* 23:31–37
158. Takata K, Takahashi K (1994) Cyclic sciatica—a case report. *Spine* 19(1):89–90
159. Thienpont E, Simon JP, Fabry G (1999) Sacral stress fracture during pregnancy—a case report. *Acta Orthop Scand* 70(5):525–526

160. Torkelson SJ, Le RA, Hildhal DB (1988) Endometriosis of the sciatic nerve: a report of two cases and a review of the literature. *Obstet Gynecol* 71(3):473–477
161. Trivalle C, Benharrats I, Wetterwald E, Beaufils M (1997) Sciaticque paralytante d'origine zostérienne. *Rev Med Interne* 18:991–993
162. Tubridy N, Redmond JM (1996) Neurological symptoms attributed to epidural analgesia in labour: an observational study of seven cases. *Br J Obstet Gynaecol* 103(8):832–833
163. Umo-Etuk J, Yentis SM (1997) Sciatic nerve injury and caesarean section. *Anaesthesia* 52:605–606
164. Vaisberg M (1964) Cyclic sciatica due to endometriosis. *N Y State J Med* 64(2):1983–1987
165. Varner M (1990) General medical and surgical diseases in pregnancy. In: Scott JR, Disaia PJ, Hammond CB, Spellacy WN (eds) *Danforth's obstetrics and gynecology*. Lippincott, Philadelphia, pp 495–533
166. Vercellini P, Chapron C, Fedele L, Frontino G, Zaina B, Crosignani PG (2003) Evidence for asymmetric distribution of sciatic nerve endometriosis. *Obstet Gynecol* 102(2):383–387
167. Vilos GA, Vilos AW, Haebe JJ (2002) Laparoscopic findings, management, histopathology, and outcome of 25 women with cyclic leg pain. *J Am Assoc Gynecol Laparosc* 9(2):145–151
168. Weingold AB (1990) Pelvic mass. In: Kase NG, Weingold AB, Gershenson DM (eds) *Principles and practice of clinical gynecology*. Churchill Livingstone, New York, pp 545–581
169. Weingold AB (1990) Surgical anatomy. In: Kase NG, Weingold AB, Gershenson DM (eds) *Principles and practice of clinical gynecology*. Churchill Livingstone, New York, pp 55–69
170. Weinreb JC, Wolbarsht LB, Cohen JM, Brown CEL, Maravilla KR (1989) Prevalence of lumbosacral intervertebral disk abnormalities on MR images in pregnant and asymptomatic non-pregnant women. *Radiology* 170:125–128
171. Williams PL, Warwick R, Dyson M, Bannister LH (1989) The spinal nerves. In: Williams PL, Warwick R, Dyson M, Bannister LH (eds) *Gray's anatomy*. Churchill Livingstone, New York, pp 1123–1153
172. Wurtz LD, Peabody TD, Simon MA (1999) Delay in the diagnosis and treatment of primary bone sarcoma of the pelvis. *J Bone Joint Surg Am* 81(3):317–325
173. Yurtseven T, Zileli M, Goker EN, Tavmergen E, Hoscoskun C, Parildar M (2002) Gluteal artery pseudoaneurysm, a rare cause of sciatic pain: case report and literature review. *J Spinal Disord Tech* 15(4):330–333
174. Zager EL, Pfeifer SM, Brown MJ, Torosian MH, Hackney DB (1998) Catamenial mononeuropathy and radiculopathy: a treatable neuropathic disorder. *J Neurosurg* 88(5):827–830
175. Zanger J, Heppner F (1962) Endometriose im Wirbelloch als ursache einer periodischen Wurzelneuralgie. *Geburtsh Frauenheilk* 22:1482–1493
176. Zonenshayn M, Edgar MA, Lavyne MH (2000) Removal of a lumbar melanotic schwannoma via the far-lateral approach in a patient with Carney complex. Case report. *J Neurosurg* 92(2 Suppl):241–245