

CLINICAL NOTES

The Lumbar Herniated Disk of Pregnancy: A Report of Six Cases Identified by Magnetic Resonance Imaging

Myron M. LaBan, MD, Nadine S. Rapp, MD, Paul von Oeyen, MD, Joseph R. Meerschaert, MD

ABSTRACT. LaBan MM, Rapp NS, von Oeyen P, Meerschaert JR. The lumbar herniated disk of pregnancy: a report of six cases identified by magnetic resonance imaging. *Arch Phys Med Rehabil* 1995;76:476-9.

• Although the mechanical and positional stresses of pregnancy are the primary inciting factors contributing to lumbosacral pain accompanying gestation, in approximately 1:10,000 cases a herniated disk (HNP) can be identified as the proximal cause of pain. Six patients are described, all of whom without antecedent history of pain presented with acute, disabling, gestational lumbosacral, and sciatic radiculopathy. Their ages ranged from 29 to 36, their parity from 0 to 1, and their gestational age at onset of symptoms from 6 weeks to 32 weeks. Each by magnetic resonance imaging (MRI) was identified as having an HNP, 2 at the L4-5 level and 4 at the L5-S1 level. During pregnancy, an MRI evaluation permits a detailed spinal examination without the ionizing effects of x-ray and its acknowledged biological risk to the developing fetus. This potential for an immediate and accurate diagnosis has significant implications for the management and subsequent planning of delivery.

© 1995 by the American Congress of Rehabilitation Medicine and the American Academy of Physical Medicine and Rehabilitation

Approximately 50% of all pregnant women will experience some degree of low back pain during their gestation, most often during the 5th to 7th months.¹⁻⁴ Multiple causative factors have been cited, including the hormonal effects of relaxin secreted by the corpus luteum, the mechanical changes exerted on the abdominal and paraspinal musculature, and the pressure placed on the inferior vena cava with a subsequent reduction in venous return from the pelvis and lower extremities. Multiple studies of the effects of age, weight gain, birth weight, and parity on gestational back pain remain controversial.^{5,6} The most recent reports, however, suggest that these factors do not have a significant influence on the development of back pain during pregnancy.^{3,4,7,8}

A herniated disk (HNP) during pregnancy as a proximal cause of low back pain has been an uncommon occurrence with a reported incidence of 1:10,000 cases.⁹ These patients may present with radicular pain and paresthesias with variable signs of associated muscle weakness and reflex changes. There does not appear to be an increased prevalence of disk abnormalities in the gestational state, although lumbosacral disk bulges or frank herniations are not unusual in women of childbearing age.⁷ In general, the prevalence of disk bulges and multiple disk abnormalities increases with age.¹⁰ The common mechanical causes of low back pain during pregnancy usually respond readily to conservative treatment. However, intractable radicular pain when unresponsive to medical management and accompanied by progressive neurological signs may require further electrodiagnostic and

neuroimaging studies for an appropriate diagnosis and treatment. When an HNP is identified as the source of gestational low back pain, additional concerns arise regarding subsequent treatment and management of the delivery.

During pregnancy, noninvasive imaging without the potentially hazardous effects of ionizing radiation to the fetus is now possible with magnetic resonance imaging (MRI). MRIs are presently obtained during pregnancy to complement ultrasound in the evaluation of in utero fetal anomalies and to further define and delineate pelvic masses.¹¹⁻¹³ Its ability to provide detailed imaging of the spine has been compared favorably with computed tomography and myelography.^{5,11}

Six patients are reviewed, all of whom without antecedent history of pain, presented with acute, disabling, gestational lumbosacral, and sciatic radiculopathy. Their clinical presentations and physical examinations were correlated with abnormalities as visualized on spinal MRI (table).

CASE REPORTS

Case 1

A 35-year-old G₂P₁ woman presented at 29 weeks gestation with severe left lower extremity pain, numbness in the left foot, and an inability to ambulate. A physical examination showed mild weakness in the left tibialis anterior (TA) and extensor hallucis longus (EHL) muscles. A decreased sensation of the left lateral calf and medial foot also were identified. She was admitted to the hospital for pain control with intramuscular narcotics. An electromyograph (EMG) showed a moderate L4 radiculopathy with 2 to 3 plus positive waves in the left TA and EHL as well as the paraspinal muscles at the left L3-L5 levels. An MRI demonstrated a left L4-5 disk herniation with sequestered fragments (fig 1). An additional bulging disk was reported at L5-S1. After 5 days of bed rest and continuing intramuscular pain medications, her symptoms markedly improved, and she was subsequently discharged. She returned at 34 weeks with preterm rupture of the membranes and the rapid onset of labor. Within 3 hours, a healthy child was delivered vaginally.

From the Department of Physical Medicine and Rehabilitation (Drs. LaBan, Rapp, Meerschaert), and the Department of Obstetrics and Gynecology (Dr. von Oeyen), William Beaumont Hospital, Royal Oak, MI.

Submitted for publication September 21, 1994. Accepted in revised form December 9, 1994.

No commercial party having a direct financial interest in the results of the research supporting this article has or will confer a benefit upon the authors or upon any organization with which the authors are associated.

Reprint requests to Myron M. LaBan, MD, Department of Physical Medicine and Rehabilitation, William Beaumont Hospital, 3601 West 13 Mile Road, Royal Oak, MI 48073.

© 1995 by the American Congress of Rehabilitation Medicine and the American Academy of Physical Medicine and Rehabilitation
0003-9993/95/7605-3243\$3.00/0

Summary of Case Reports

Patient	Age	Gravida	Para	Gestational Age at Onset of Symptoms	MRI Findings	EMG
1	35	2	1	29 weeks	HNP L4-5 left	Left L4 radic
2	32	2	0	29 weeks	HNP L5-S1 right	Absent H reflex
3	36	3	1	20 weeks	HNP L5-S1 right	Right S1 radic
4	30	2	1	32 weeks	HNP L4-5 right	Right L5-S1 radic
5	29	1	0	6 weeks	HNP L5-S1 left	Not performed
6	35	4	0	10 weeks	HNP L5-S1 left & central	Not performed

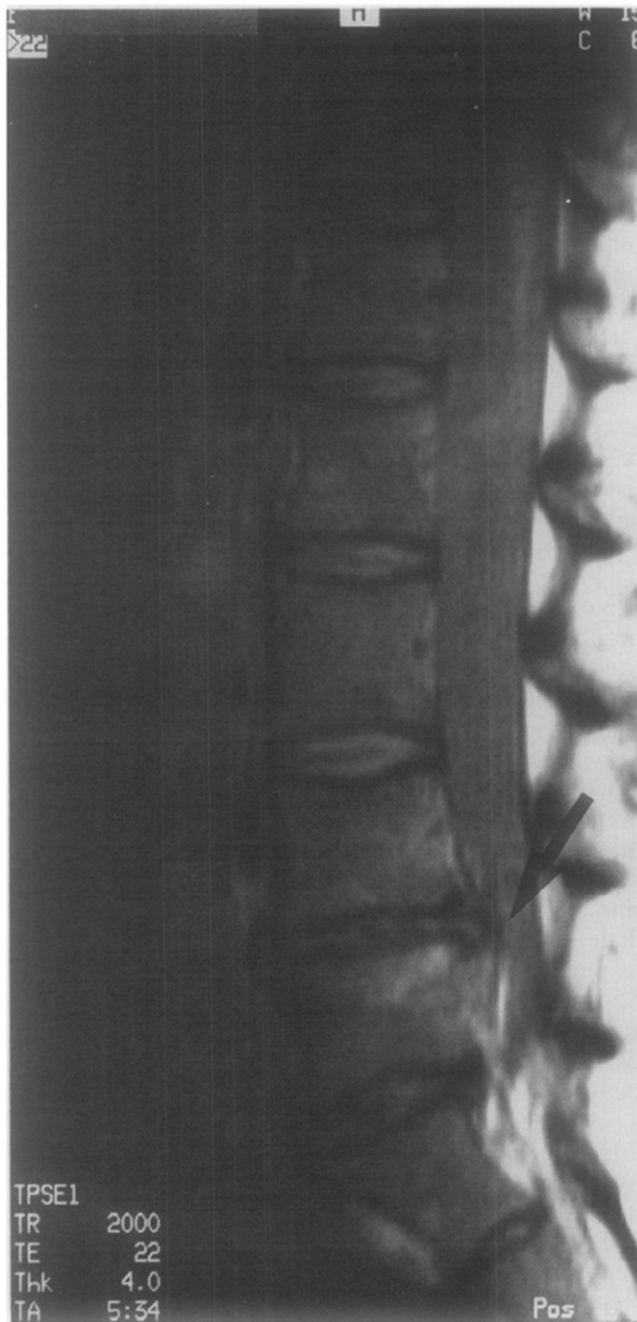


Fig 1—Proton density sagittal MRI image of the lumbosacral spine demonstrating an HNP at L4-5 to the left with a possible sequestered fragment. A moderate degenerative disk at L4-5 with decreased signal intensity and intervertebral disk height also is visualized.

Case 2

A 32-year-old G₂P₀ woman presented with intractable back pain at 29 weeks of gestation. A physical examination showed an absent right achilles reflex and a weak EHL. The EMG was normal; however, the H reflex was absent bilaterally suggesting S1 root compromise. An MRI demonstrated a HNP at the right L5-S1 level. Her symptoms responded to conservative treatment. Because of the history of an HNP, she was delivered electively by cesarean section at 39 weeks with spinal anesthesia.

Case 3

A 36-year-old G₃P₁ woman was admitted to the hospital at 20 weeks gestation with complaints of low back and disabling buttock pain, unable to sit or stand. An EMG demonstrated a moderate right S1 radiculopathy with increased insertional activity and 2 plus positive waves in the gluteus maximus, EHL, flexor digitorum longus, gastrocnemius, and first dorsal interossei. An MRI showed a large right focal disk herniation with compromise of the S1 nerve root (fig 2). Degenerative disk disease at the L5-S1 level also was noted. With progressive neurological deficits including bladder incontinence and intractable back pain, a lumbar laminectomy with discectomy was performed. Postoperatively her symptoms rapidly resolved. A healthy child was delivered by cesarean section at 39 weeks with general anesthesia due to concurrent fetal bradycardia.

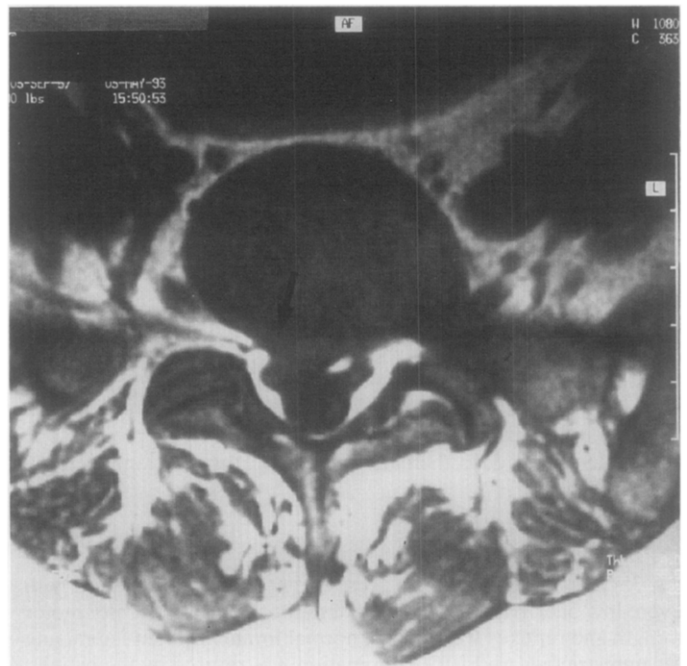


Fig 2—Axial T1-weighted MRI image of the lumbosacral spine with evidence of a large focal disk herniation at L5-S1 to the right with compromise of the S1 nerve root.

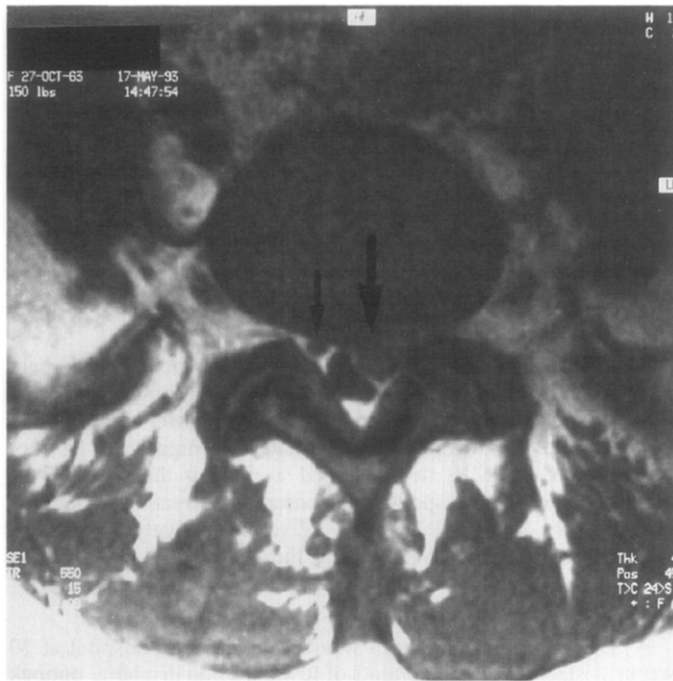


Fig 3—Axial T1-weighted MRI image of the lumbosacral spine showing a large focal disk herniation at L5-S1 to the left (large arrow) with compromise of the S1 nerve root. A smaller arrow demonstrates the uncompromised right S1 nerve root.

Case 4

A 30-year-old G₂P₁ woman presented at 32 weeks gestation with complaints of right buttock and lower extremity pain. A physical examination showed sacroiliac joint tenderness, restricted right straight leg raising at 30°, and positive crossed straight leg raising at 45°. An EMG demonstrated a right L5-S1 radiculopathy with 2 plus positive waves seen in the TA and the extensor digitorum brevis as well as the paraspinal muscles at L4-S1. A MRI showed a moderate right posterolateral disk protrusion at the L4-5 level with probable compromise of the L5 nerve root. Her pain subsequently responded to conservative treatment. With MRI evidence of an HNP, she delivered at term by cesarean section with spinal anesthesia.

Case 5

A 29-year-old G₁P₀ woman presented at 6 weeks gestation with complaints of intractable, disabling low back pain. She refused EMG examination. An MRI was performed that showed a large focal left disk herniation at the L5-S1 level with compromise of the S1 nerve root (fig 3). A moderate central disk protrusion at L4-5 with mild compression of the thecal sac also was noted. The patient miscarried at 11 weeks of gestation. With progressive, intractable pain 4 days thereafter, she had a lumbar laminectomy with discectomy.

Case 6

A 35-year-old G₁P₀ woman presented at 10 weeks gestation with severe low back pain of one week duration. Lower extremity motor strength and reflexes were within normal limits. Straight leg raising was unrestricted. An EMG examination was refused by the patient. An MRI was performed showing a large HNP centrally and to the left at the L5-S1 level with S1 root compromise. Her pain responded to conservative treatment. She subsequently carried to

term and delivered by elective cesarean section with general anesthesia due to the history of an HNP.

DISCUSSION

There are multiple factors contributing to low back pain during pregnancy. In 1983, LaBan et al⁹ reported an incidence of 1:10,000 HNPs during pregnancy. Over 10 years, 5 patients with HNPs in a series of 48,760 consecutive deliveries were identified. Their ages ranged from 24 to 32 years, with an average of 28 years. This present series of 6 patients, however, was accumulated within 1 year. Their ages ranged from 29 to 36 years with an average of 33 years. The average gestational age of symptom onset was 21 weeks, corresponding to the 6th month of gestation. Previous reports have also described an increasing incidence of low back pain during pregnancy in the 5th to 7th months.¹⁻³ As is apparent in comparing the two studies, the risk of a lumbar disk herniation is increased with advancing maternal age. In the United States, the average age of the primiparous woman also has significantly increased. The percentage of primiparous women age 30 to 34 has grown from 10% to 26.2% between 1970 and 1990 and among women age 35 to 39 from 6.5% to 21.1%. In the last 20 years, at delivery the proportion of women greater than 30 years of age has also increased from 17.7% to 30.2%.¹⁴ Clearly, a different population of patients is encountered during pregnancy today than just a decade ago. Inherent to advancing maternal age are physiological and anatomical changes that may predispose the lumbar disk to herniation.

Primiparity as well as advancing maternal age singularly and together have been cited as major risk factors predisposing to cesarean delivery.¹⁴ In this series, half of the patients were primiparous, with an average age of 33 years. Three carried to term and were subsequently delivered by cesarean section solely because of the presence of a HNP. However, two also had additional problems of fetal distress. One patient with a rather precipitous onset of labor was delivered vaginally within 3 hours. Undoubtedly, the presence of an identified or suspected HNP has in the past influenced the method of delivery. Traditionally, cesarean section has been the preferred route of delivery with the anticipation that during labor increasing epidural venous pressures could precipitate progressive neurological dysfunction. Epidural venous pressure is an indirect measure of cerebral spinal fluid (CSF) pressure, which in turn is a direct reflection of the central venous pressure.¹⁵ However, during uterine contractions, increases in CSF pressure have been reported to be directly proportional to the intensity of the perceived pain that subsequently influences the amount of concomitant skeletal muscle activity.¹⁶ The elevations in both CSF and epidural pressure are therefore not directly related to contractions of the uterine musculature itself but rather are a product of the reflex responses of skeletal muscles to pain. These increases in CSF pressure may be curtailed by inhibiting the perception of pain, ie, by using regional block anesthesia.¹⁶ In fact, this type of anesthesia has been recommended for the management of labor and delivery when elevated CSF pressures are to be avoided.¹⁶ Although the appropriate route of delivery for patients with an HNP remains controversial, the advantages of an MRI in the evaluation of the gravid

patient with low back pain and a suspected HNP appear to be incontrovertible. In an earlier report, an initial decision to terminate a pregnancy was reconsidered when the source of intractable lumbosacral pain was identified as an HNP by MRI examination with the patient subsequently responding to conservative treatment.¹⁷

Recently the MRI has been extensively employed in the management of the gravid patient complementing the ultrasound evaluation of in utero fetal anomalies and pelvic masses as well as detecting abnormalities of cervical function.¹¹⁻¹³ The MRI examination permits a noninvasive detailed spinal image without the potential adverse effects of ionizing radiation to the fetus. To date, there have been no reported cases of hazardous effects on the developing fetus. Although long-term studies are currently not available, Evans and colleagues¹⁸ failed to identify an increased incidence of infertility or low-birth-weight infants in MRI workers when compared with pregnant women working at other jobs or at home. They did, however, report a slightly increased likelihood of miscarriages among MRI workers when compared with controls, which they attributed to the older age of the MRI workers.

In this study, each of the six patients were imaged with sagittal T1-weighted proton density and T2-weighted MRIs as well as axial T1-weighted images. The MRI has an additional advantage of direct imaging in more than one plane and has an equal if not better resolution capability than computed tomography,¹¹ without the additional hazard of ionizing radiation. The HNP on MRI appears bright, and the fibrous tissue of the annulus fibrosus appears dark. Narrowing of the disk and a decrease in signal intensity as well as effacement of epidural fat also suggest an HNP.¹¹ McCarthy and colleagues¹² have postulated that during pregnancy the high incidence of disk bulging and herniation occurring without loss of signal intensity from the nucleus pulposus may be attributed to the hormonal effects of relaxin producing ligamentous relaxation of the posterior longitudinal ligament.

In patients who demonstrated focal neurological signs including altered reflexes, muscle weakness, dermatomal sensory loss, and/or EMG abnormalities, the findings correlated with the root level of disk herniation as shown by MRI. Abnormalities of the lumbosacral spine as visualized by MRI must be carefully interpreted as they relate to the patient's clinical presentation owing to the high prevalence of anatomic abnormalities discovered in asymptomatic people.¹⁰ Four of the six patients had an EMG performed before spinal imaging. All demonstrated significant electrodiagnostic evidence of lumbar root compromise at the level of the HNP as identified by MRI.

The treatment of the gravid patient with a documented HNP includes among other conservative approaches bed rest, thermotherapy, gestational lumbosacral corseting, and when appropriate, an exercise program to maintain lumbar and hamstring flexibility as well as strengthening the abdominal

musculature. Analgesics are prescribed sparingly in pregnancy. However, acetaminophen and cyclobenzaprine as well as narcotics have all been safely employed in these patients.⁸ In this series, the patients were managed by a medical team that included the obstetrician and a maternal-fetal medicine specialist as well as the physiatrist. Four of the six were successfully carried to delivery with conservative treatment. However, one patient required urgent surgical intervention when bladder incontinence compounded medical treatment. After a miscarriage, another subsequently came to a discectomy for intractable pain.

As the age of primiparity continues to increase, the incidence of an HNP during pregnancy is also increasing. The MRI provides a noninvasive and accurate method of visualizing the presence of an HNP without exposing the fetus to ionizing radiation.

References

1. Fast A, Shapiro D, Ducommun EJ, Friedmann LW, Bouklas T, Floman Y. Low-back pain in pregnancy. *Spine* 1987;12:368-71.
2. Ostgaard HC, Andersson GBJ, Karlsson K. Prevalence of back pain in pregnancy. *Spine* 1991;16:549-52.
3. Runge JL. Low back pain during pregnancy. *Orthopedics* 1993;16:1339-44.
4. Berg G, Hammar M, Moller-Nielsen J, Linden U, Thorblad J. Low back pain during pregnancy. *Obstet Gynecol* 1988;71:71-5.
5. Mantle MJ, Greenwood RM, Currey HLF. Backache in pregnancy. *Rheumatol Rehabil* 1977;16:95-101.
6. Ostgaard HC, Andersson GB, Wennergren M. The impact of low back and pelvic pain in pregnancy on the pregnancy outcome. *Acta Obstet Gynecol Scand* 1991;70:21-4.
7. Weinreb JC, Wolbarsht LB, Cohen JM, Brown CEL, Maravilla KR. Prevalence of lumbosacral intervertebral disk abnormalities on MR Images in pregnant and asymptomatic nonpregnant women. *Radiology* 1989;170:125-8.
8. Alexander JT, McCormick PC. Pregnancy and discogenic disease of the spine. *Neurosurg Clin North Am* 1993;4:153-9.
9. LaBan MM, Perrin JCS, Latimer FR. Pregnancy and the herniated lumbar disc. *Arch Phys Med Rehabil* 1983;64:319-21.
10. Jensen MC, Brant-Zawadzki MN, Obuchowski N, Modic MT, Malkasian D, Ross JS. Magnetic resonance imaging of the lumbar spine in people without back pain. *New Engl J Med* 1994;331:69-73.
11. McCarthy SM, Filly RA, Stark DD, Callen PW, Golbus MS, Hricak H. Magnetic resonance imaging of fetal anomalies in utero: early experience. *AJR* 1985;145:677-82.
12. McCarthy SM, Stark DD, Filly RA, Callen PW, Hricak H, Higgins CB. Obstetrical magnetic resonance imaging: maternal anatomy. *Radiology* 1985;154:421-5.
13. Weinreb JC, Brown CE, Lowe TW, Cohen JM, Erdman WA. Pelvic masses in pregnant patients: MR and US Imaging. *Radiology* 1986;159:717-24.
14. Parrish KM, Holt VL, Easterling TR, Connell FA, LoGerfo JP. Effect of changes in maternal age, parity, and birth weight distribution on primary cesarean delivery rates. *JAMA* 1994;271:443-7.
15. Johnston GM, Rodgers RC, Tunstall ME. Alteration of maternal posture and its immediate effect on epidural pressure. *Anesthesia* 1989;44:750-2.
16. Marx GF, Oka Y, Orkin LR. Cerebrospinal fluid pressures during labor. *Am J Obstet Gynecol* 1962;84:213-9.
17. LaBan MM, Viola S, Williams DA, Wang A. Magnetic resonance imaging of the lumbar herniated disc in pregnancy. *Am J Phys Med Rehabil*. In press.
18. Evans JA, Savitz DA, Kanal E, Gillen J. Infertility and pregnancy outcome among magnetic resonance imaging workers. *J Occup Med* 1993;35:1191-5.