

# Anatomical, Clinical, and Electrodiagnostic Features of Radial Neuropathies

Leo H. Wang, MD, PhD<sup>a,\*</sup>, Michael D. Weiss, MD<sup>b</sup>

## KEYWORDS

• Radial • Posterior interosseous • Neuropathy • Electrodiagnostic study

## KEY POINTS

- The radial nerve subserves the extensor compartment of the arm.
- Radial nerve lesions are common because of the length and winding course of the nerve.
- The radial nerve is in direct contact with bone at the midpoint and distal third of the humerus, and therefore most vulnerable to compression or contusion from fractures.
- Electrodiagnostic studies are useful to localize and characterize the injury as axonal or demyelinating.
- Radial neuropathies at the midhumeral shaft tend to have good prognosis.

## INTRODUCTION

The radial nerve is the principal nerve in the upper extremity that subserves the extensor compartments of the arm. It has a long and winding course rendering it vulnerable to injury. Radial neuropathies are commonly a consequence of acute traumatic injury and only rarely caused by entrapment in the absence of such an injury. This article reviews the anatomy of the radial nerve, common sites of injury and their presentation, and the electrodiagnostic approach to localizing the lesion.

## ANATOMY OF THE RADIAL NERVE

### *Course of the Radial Nerve*

The radial nerve subserves the extensors of the arms and fingers and the sensory nerves of the extensor surface of the arm.<sup>1-3</sup> Because it serves the sensory and motor

---

Disclosures: Dr Wang has no relevant disclosures. Dr Weiss is a consultant for CSL-Behring and a speaker for Grifols Inc. and Walgreens. He has research support from the Northeast ALS Consortium and ALS Therapy Alliance.

<sup>a</sup> Department of Neurology, University of Washington Medical Center, University of Washington, Box 356465, 1959 Northeast Pacific Street, Seattle, WA 98195, USA; <sup>b</sup> Department of Neurology, University of Washington Medical Center, 1959 Northeast Pacific Street, Seattle, WA 98195, USA

\* Corresponding author.

E-mail address: [leowang@uw.edu](mailto:leowang@uw.edu)

Phys Med Rehabil Clin N Am 24 (2013) 33–47

<http://dx.doi.org/10.1016/j.pmr.2012.08.018>

1047-9651/13/\$ – see front matter © 2013 Elsevier Inc. All rights reserved.

[pmr.theclinics.com](http://pmr.theclinics.com)

nerves of the dorsal arm, it derives innervation from most-to-all of the spinal roots that participate in the brachial plexus (C5–C8 with inconstant T1 contribution), and all three derived trunks. The three trunks divide into the anterior and posterior division. The recombined posterior division continues on as the posterior cord. Both the posterior division and posterior cord serve the posterior “extensor” compartment.<sup>4</sup> The posterior cord follows posterior to the axillary artery and divides into two terminal branches, the axillary nerve and the radial nerve. The axillary nerve lies lateral to the radial nerve and winds around the surgical neck of the humerus. The radial nerve continues posteriorly following the axillary artery and subsequently the deep brachial artery. From the medial side of the humerus, the radial nerve quickly winds back posteriorly around the spiral groove of the humerus.

In the spiral groove, it passes through the medial and lateral heads of the triceps. After it turns in the spiral groove to the dorsal side and becomes lateral to the humerus, it pierces the lateral intermuscular septum (around the distal one-third of the humeral length<sup>5,6</sup>) and courses around the lateral humeral condyle, entering the anterior compartment. At the elbow, it divides in the posterior interosseous nerve (PIN) and the superficial branch of the radial nerve. The superficial branch of the radial nerve goes under the brachioradialis and extends down the radius border only to emerge before the hand and the anatomic snuffbox. The PIN travels deep through the supinator muscle by the arcade of Frohse (a tendinous structure in one- to two-thirds of the population) into the middle of the forearm. In the forearm, it is in contact with the interosseous membrane.

### ***Motor Innervation***

The first two motor branches of the radial nerve innervate the forearm extensors, the triceps, and anconeus (**Fig. 1**). These branches come off within or proximal to the spiral groove. The radial nerve only innervates the lateral and medial heads of the triceps; the axillary nerve innervates the third (long) head.<sup>7</sup> After the spiral groove, the radial nerve gives off branches to the brachialis, brachioradialis, and extensor carpi radialis longus. The brachialis and brachioradialis are two of the three forearm flexors. The biceps brachii is the third forearm flexor. The biceps is usually innervated by the musculocutaneous nerve and flexes the forearm in supination. The brachialis is innervated by the musculocutaneous nerve with some contribution to the lateral part by the radial nerve,<sup>8–13</sup> and flexes the forearm in all positions. The brachioradialis is usually the sole radial-innervated forearm flexor and flexes the forearm midway between supination and pronation. The extensor carpi radialis longus is one of several wrist extensors. However, it is the only wrist extensor that is innervated by the radial nerve proximal to the elbow and the PIN and is spared in PIN lesions. The extensor carpi radialis longus is a wrist extensor when the hand is deviated radially.

The first muscle innervated by the PIN is the supinator. The PIN innervates the muscle before the nerve enters the arcade of Frohse.<sup>14</sup> The supinator rotates the forearm outward to result in the palm being face up. The next group of muscles innervated by the PIN is the superficial extensor group comprised of the two other wrist extensors (extensor carpi radialis brevis and extensor carpi ulnaris), and the finger extensors (extensor digitorum communis, extensor digiti minimi, extensor indicis, extensor pollicis longus, abductor pollicis longus, and extensor pollicis brevis). The extensor carpi ulnaris is a wrist extensor when the hand is deviated in the ulnar direction. The extensor digitorum communis extends the metacarpophalangeal joints of the second through fifth digits, whereas the extensor indicis and the extensor digiti minimi extend the same joint for the second and fifth digit, respectively. The extensor pollicis longus extends the thumb into the thumbs-up position. The extensor pollicis brevis extends the thumb at the metacarpophalangeal joint. The abductor pollicis longus abducts the thumb at the wrist.

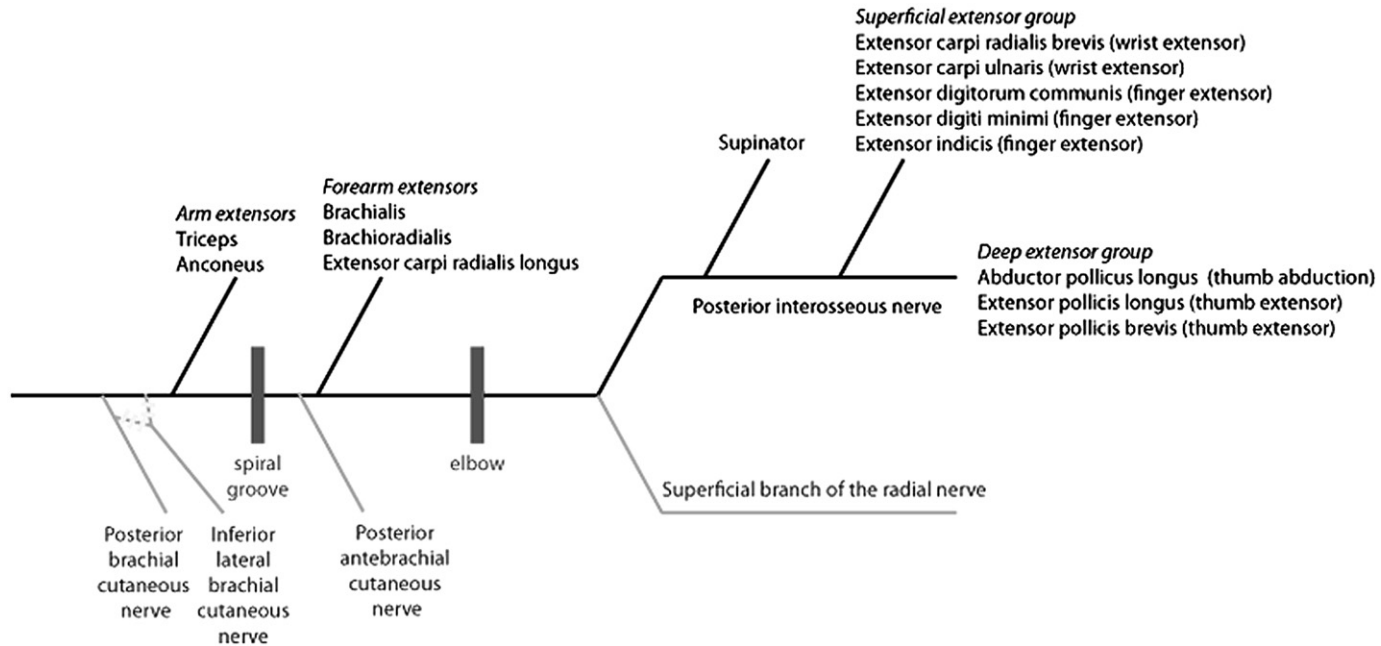


Fig. 1. Branches of the radial nerve. Motor branches are black and sensory branches are gray.

### ***Sensory Innervation***

---

The sensory branches of the radial nerve supply sensation to the dorsum of the arm, forearm, and hand. There are three major sensory branches: (1) the posterior brachial cutaneous nerve, (2) the posterior antebrachial cutaneous nerve, and (3) the superficial branch of the radial nerve. There is great variation in the sensory area innervated by the radial nerve primarily because of overlapping contributions from other nerves.

The posterior brachial cutaneous nerve (posterior cutaneous nerve of arm) originates before the nerve branch to the triceps. This sensory branch covers the midline posterior arm. The inferior lateral brachial cutaneous nerve supplies the lateral arm below the shoulders and may be a separate sensory branch off the main radial nerve or the posterior brachial cutaneous nerve. The sensory territory of the arm is shared with the superior lateral brachial cutaneous nerve, which arises from the axillary nerve, and the intercostobrachial and medial brachial cutaneous nerves.

The posterior antebrachial cutaneous nerve (posterior cutaneous nerve of the forearm) originates between the nerve branch to the triceps and the spiral groove. This sensory branch covers the midline posterior forearm. The sensory territory of the forearm is shared with the medial antebrachial cutaneous nerve and the lateral antebrachial cutaneous nerve that is the terminal branch of the musculocutaneous nerve.

The superficial branch of the radial nerve is a terminal branch of the radial nerve along with the PIN. This sensory branch covers the lateral two-thirds of the dorsum of the hand, extending up to the proximal first 3.5 digits. The sensory territory of the hand is shared with the median nerve that wraps over the palmar surface to cover the tips of the first 3.5 digits and the dorsal ulnar cutaneous nerve from the ulnar nerve. The PIN is mainly a terminal motor branch, but contains few sensory fibers that innervate the ligaments of the radiocarpal, intercarpal, and carpometacarpal joints.<sup>15</sup>

The overlapping contributions from other nerves are important,<sup>16,17</sup> because this may explain why radial nerve lesions are not always accompanied by sensory deficits. These findings may be confounded by the hirsute nature of the dorsal surface of the arm.

### **ETIOLOGY AND CLINICAL PRESENTATION**

Radial nerve lesions are commonly caused by traumatic injury from the length and winding course of the radial nerve about the humerus and uncommonly from entrapment in the absence of acute trauma. Lesions can occur anywhere along its course. Etiologies can include direct external nerve compression or contusion from trauma. Common lesions involve contusion from humeral fractures or external compression affecting the nerve at the mid-arm, contusions from proximal radial fractures, or inflammation around the elbow affecting the PIN. The nerve was the most commonly injured peripheral nerve during World War I, accounting for around one-fourth of peripheral nerve injuries.<sup>18</sup> One conjecture is that the nerve was injured when arms were raised in shock to protect the body or head from flying bullets. In the current era, combat-related wounds are more complicated; however, there was still a significant increase in radial nerve lesions when the US military entered into the Iraq conflicts.<sup>19</sup>

### ***Lesions in the Axilla***

---

Lesions in the axilla affecting the posterior cord or the radial nerve are uncommon. These lesions can result from compression by crutches of the nerve against the humerus or muscles of the axilla ("crutch paralysis"), missile injuries, shoulder

dislocation, or proximal humeral fracture. Such lesions would result in weakness of all radial-innervated muscles (most prominently a wrist drop); loss of the triceps and brachioradialis reflexes; and loss of sensation along the dorsum of the arm.

### ***Lesions in the Arm***

---

Lesions in the arm are the most common causes of radial nerve lesions. There are two areas where the radial nerve is in direct contact with the humeral bone without any interposing muscle or fascial tissue as protection and therefore the most vulnerable.<sup>20</sup> One such area is the distal third of the humeral bone where the nerve lies directly lateral to the bone, which is the reason why fracture of the humerus at the supracondylar humeral shaft is the most common cause of a radial nerve lesion in the upper arm. The second area where the radial nerve is in direct contact with the humerus is approximately 6 cm centered around the midshaft of the humerus where the potentially palpable deltoid tuberosity is situated. Here the radial nerve lies posterior to the bone and is especially susceptible to injury in midshaft fractures (occurring in about 12% of such fractures<sup>21</sup>) and iatrogenic injury after operative fixation of such fractures. Tardy radial neuropathies also result from the nerve being compressed or engulfed by callus formed over time after fractures.

The midshaft segment of the radial nerve directly behind humerus is also susceptible to direct compressive lesions. This area is commonly thought to be associated with the “spiral groove.” However, this may be more of a conceptual term than a real structural entity.<sup>20</sup> Compressive lesions in this area are responsible for the most classical radial nerve injury, often called “Saturday night palsy” or “sleep paralysis.” The common folklore is that such palsies affect patients who drape their arm over a hard chair or sofa edge after deep sleep made deeper by imbibing alcohol or sedatives. However, intense interrogation does not always elicit a history of inebriation or draping the arm over a hard object. Other possible compressive methods can include compressing the arm against the head or body of the patient or his or her partner during sleep. Such similar pathogenesis also explains why radial nerve palsies occur as a consequence of arm positioning during anesthesia.<sup>22</sup> This site is also susceptible to compressive neuropathies in patients with hereditary neuropathy with liability to pressure palsies.<sup>23</sup>

Other rare manifestations include compression by tendinous fibers of the lateral head of the triceps, tourniquets, and arm muscles during vigorous or repetitive arm exercise. Patients with such lesions usually present with wrist and finger drops. There is variable sparing of muscles innervated by the radial nerve above the elbow depending on the location of the lesion and differential fascicular involvement. Lesions at the “spiral groove” tend to have weakness of radial-innervated muscles except for arm extension because the motor branch to the triceps and anconeus splits off before the midshaft area. Weakness of the brachialis muscle may or may not be present (depending on differential fascicular involvement). Because the posterior brachial cutaneous nerve also splits off before the midshaft area, if sensation is lost, it only affects the forearm or hand. The triceps reflex is spared. Lesions distal to the “spiral groove” above the elbow may spare the brachioradialis or extensor carpi radialis longus muscles.

### ***Lesions at the Elbow***

---

Lesions at the elbow mainly affect muscles innervated by the PIN. Traumatic contusions to the nerve can be the result of fractures of the proximal radius or midarm fractures of the radius or ulna and iatrogenic injury during repair of such fractures and arthroscopic elbow procedures. Nerve entrapment can occur at the tendinous edge

of the extensor carpi radialis, the distal edge of the supinator, and the arcade of Frohse. Compressive lesions to the nerve can be caused by inflamed hypertrophied synovium in rheumatoid arthritis and soft tissue masses and tumors, such as lipomas, myxomas, ganglia from the elbow joints, neurofibromas, schwannomas, chondromas, traumatic aneurysms of the posterior interosseous artery, and hemangiomas.<sup>24-34</sup> A tardy posterior interosseous neuropathy can also occur after unreduced radial head dislocation and proximal ulnar fractures.<sup>35</sup>

The radial tunnel and its associated syndrome seem to be orthopedic concepts that engender much skepticism from neurologists. The radial tunnel is located anterior to the proximal radius after the radial capitulum and before the PIN travels below the superficial portion of the supinator muscle at the arcade of Frohse. The brachioradialis, extensor carpi brevis, and longus form the lateral border and the biceps tendon and brachialis muscle form the medial border. Fibrous bands, muscles, or blood vessels within this area have been implicated in PIN entrapment.<sup>36</sup> Other noncompressive causes of posterior interosseous neuropathy are acute brachial plexus neuropathy (brachial neuritis) or multifocal motor neuropathy.

The radial tunnel syndrome is associated with chronic pain without any significant motor deficits. It is mainly characterized by localized tenderness over the lateral part of the proximal forearm, an area distal to the lateral epicondyle, and worsened by supination or finger and wrist extension. Pain may confound the exact degree of weakness. The crux of the controversy is whether neurologists believe there is true involvement of the PIN because there is usually none of the expected finger greater than wrist extensor weakness. Proponents believe that chronic damage and inflammation of the extensor muscle attachment to the epicondyle by the supinator, extensor carpi radialis brevis, extensor digitorum, extensor digiti minimi, and extensor carpi ulnaris as a consequence of overuse cause an entrapment of the PIN in the radial tunnel and argue that the pain is from impingement of the PIN pain fibers to the bone, joint, or muscle. There is significant overlap clinically between the radial tunnel syndrome and lateral epicondylitis, also known as tennis elbow, lateral tennis elbow, or lateral tendinosis, which is the result of overuse of the extensor and supinator muscles, especially with playing tennis. Radial tunnel syndrome is thought to be the reason why patients have resistant, chronic, and persistent tennis elbow. Neurologists tend to be skeptical that radial tunnel release relieves pain because of direct decompression of the PIN and believe that the division of the superficial portion of the supinator muscle itself relieves tension on the lateral epicondyle.<sup>36</sup> It is the contention of the authors that entrapment of the radial nerve at the radial tunnel is a rare occurrence and cannot be clearly established without electrophysiologic confirmation.

Typically, supination and sensation are spared in posterior interosseous neuropathies. Finger extension is more affected than wrist extension weakness, because the motor branch to the extensor carpi radialis splits off before the elbow. Therefore, the wrist deviates radially, especially when forming a fist or extending. An important examination point is that examination of ulnar-innervated muscles (while in the dropped wrist position) may demonstrate a pseudoulnar palsy as the ulnar-innervated intrinsic hand muscles insert on the extensor muscles and require coactivation of radial-innervated finger extensors.<sup>37</sup> This can be more apparent in patients with chronic radial nerve palsies where there is loss of intrinsic hand muscle strength because of prolonged disuse. Some patients with nontraumatic posterior interosseous neuropathy may complain of pain,<sup>38</sup> possibly caused by injury to the sensory fibers of the PIN that innervate the ligaments of the radiocarpal, intercarpal, and carpometacarpal joints.<sup>15</sup>

### ***Lesions of the Superficial Branch of the Radial Nerve***

---

Lesions of the superficial branch of the radial nerve cause a pure sensory syndrome known as cheiralgia paresthetica or Wartenberg disease. Traumatic contusions caused by crush or twisting injuries of the wrist or forearm can cause such a neuropathy. Entrapments are rare. Compressive lesions can be secondary to repetitive occupational pronation-supination movements, wristwatch bands, casts, or even handcuffs. Similar to “Saturday night palsy,” many patients with handcuff neuropathies are inebriated.<sup>39,40</sup> Patients typically describe pain or burning over the sensory area of the superficial branch of the radial nerve centered around the anatomic snuffbox. This can be exacerbated by pinching and gripping activities or hyperpronation provocative testing (ie, pronation of the forearm while the wrist is in ulnar flexion).

### ***Differential Diagnosis***

---

The differential diagnosis for radial nerve palsies includes other lesions along the motor pathway that subserve the activation of extensor compartment muscles of the forearm. Distally to proximally, such sites include the posterior cord, brachial plexus, cervical roots, and the cerebral cortex. Typically, there are other clues to distinguish among these sites of injury. Posterior cord lesions typically also involve deltoid weakness and sensory loss in the shoulder region. Although a C7 radiculopathy may mimic a proximal radial neuropathy, including mild sensory symptoms and signs in the radial sensory distribution in the dorsum of the hand, the usual finding also of sensory loss involving the palmar aspect of the third finger would not be seen with a radial neuropathy. When a C7 nerve root lesion is severe enough to cause muscle weakness, median-innervated muscles supplied by the C7 nerve root, such as the pronator teres and flexor carpi radialis, may also be affected excluding the diagnosis of radial neuropathy. Cerebral cortical infarcts located in the precentral “hand knob” area may cause an isolated wrist drop but are usually accompanied with signs of upper motor neuron dysfunction, such as hyperreflexia. The differential diagnosis for a partial PIN lesion may include rupture of thumb and finger extensors that can occur in rheumatoid arthritis and a focal myopathy of the finger extensors.<sup>41</sup> Rheumatologic diseases may also mimic neuromuscular weakness of the forearm extensor compartment. For instance, de Quervain tenosynovitis can cause pain in the distribution of the superficial branch of the radial nerve and is in the differential diagnosis of lesions affecting that nerve.

## **ASSESSMENT**

### ***Electrodiagnostic Testing***

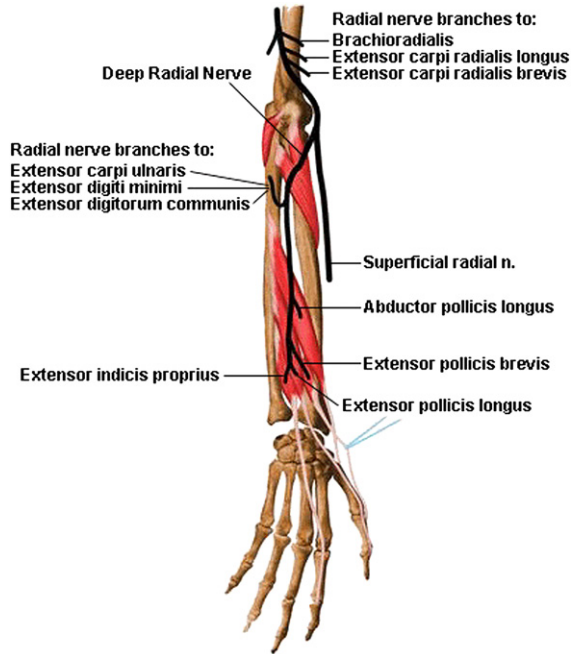
---

Electrodiagnostic testing is often the key to confirming a radial mononeuropathy and localizing the area of injury, and is considered an extension of the neurologic examination. It should involve radial sensory nerve conduction, radial motor nerve conduction, including segments in the proximal arm, and needle electromyography (EMG) study of relevant muscles (see **Fig. 1**; **Fig. 2**). Testing should also be performed to rule out other disorders that may mimic a radial neuropathy, such as C7 radiculopathy, brachial plexopathy, or mononeuropathy multiplex.

### ***Motor Nerve Conduction Studies***

---

Motor nerve conduction study of the radial nerve is most helpful in identifying the demyelinating lesions in the “spiral groove.” Motor nerve conduction study is usually performed by placing the active electrode over the belly of the extensor indicis proprius, three to four fingerbreadths from the distal ulna (**Fig. 3A**). The distal stimulation



**Fig. 2.** Muscles innervated by the radial nerve. (Copyright 2003–2004 University of Washington. All rights reserved including all photographs and images. No reuse, redistribution or commercial use without prior written permission of the authors and the University of Washington. From Teitz C, Graney D. *Musculoskeletal atlas: a musculoskeletal atlas of the human body*. Seattle (WA): University of Washington, <http://depts.washington.edu/msatlas/127.html>,2012; with permission.)

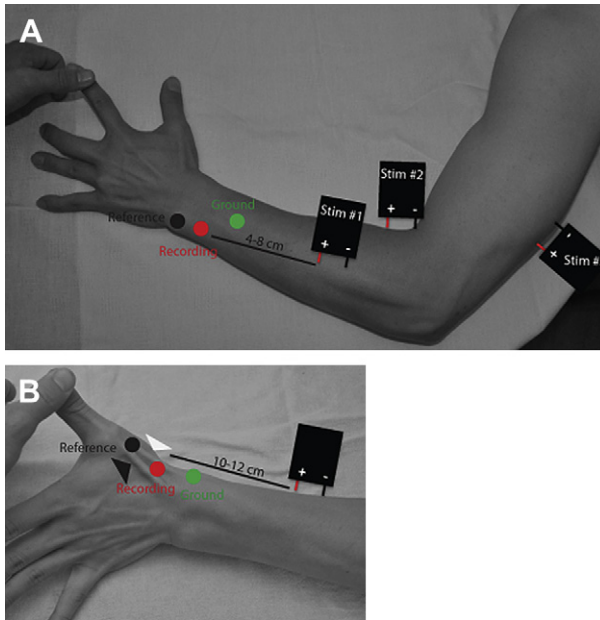
site is usually 4 to 8 cm proximal to the middle of the forearm. A second stimulation site is at the lateral epicondyle. A third stimulation site is around the “spiral groove.” Onset latency for the distal compound muscle action potential (CMAP) is usually fast, as are conduction velocities, which can be as high as 75 m/s.<sup>42</sup> Other recording sites are the extensor digitorum communis, extensor carpi ulnaris, and brachioradialis muscles.<sup>43</sup>

Conduction block or temporal dispersion can occur proximal to midshaft. The key to localizing such an injury is stimulation proximal to the “spiral groove” to detect the conduction block. Axonal loss may be estimated from the decrease in the compound motor action potential and typically occurs between 5 and 7 days after an insult. In a case series of 21 patients with nontraumatic compression-related radial neuropathy at the spiral groove and radial motor nerve conduction studies performed 7 days or later, 10% had reduced distal radial CMAP amplitude and approximately 60% had conduction block or reduced conduction velocity in the spiral groove.<sup>44</sup> In the same case series, there was clinical follow-up on 23 patients, who all experienced complete recovery.<sup>44</sup> In a small case series of 33 patients with traumatic radial neuropathies presented by Malikowski and colleagues,<sup>45</sup> the absence of radial CMAP was associated with 65% partial or full recovery, and the presence of radial CMAP was associated with 85% partial or full recovery.

### **Sensory Nerve Conduction Studies**

Sensory nerve conduction study of the radial nerve typically assesses just the superficial branch of the radial nerve and is recorded at the anatomic stuff box (see **Fig. 3B**)





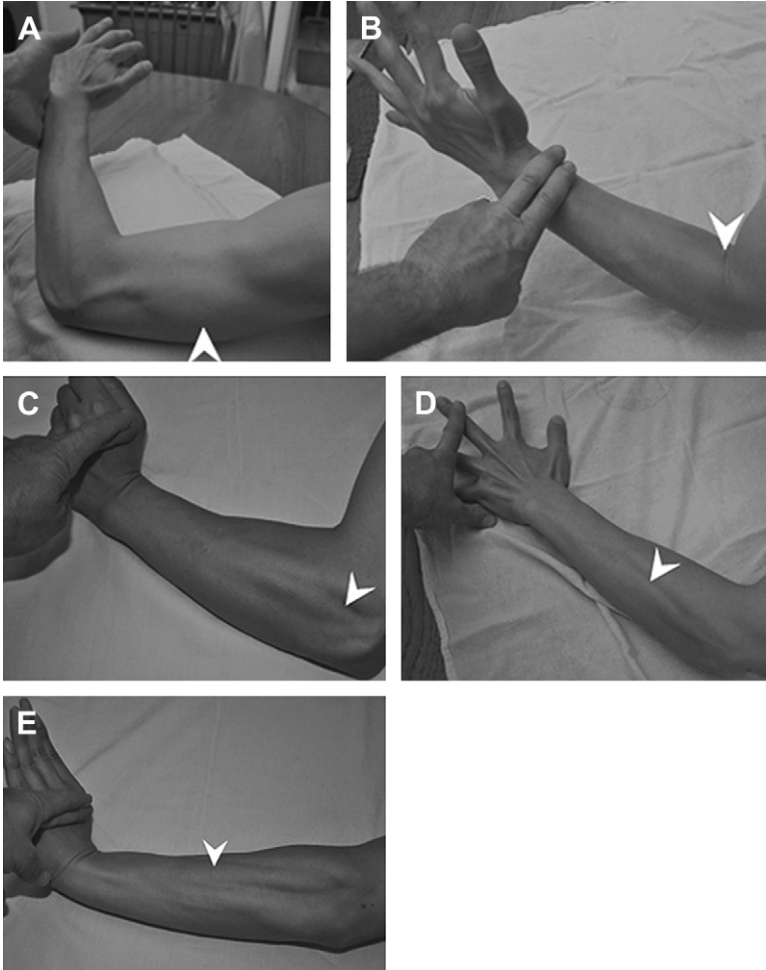
**Fig. 3.** Radial nerve conduction studies. (A) Radial motor nerve conduction study recorded from the extensor indicis proprius. The recording electrode is placed two fingerbreadths or approximately 4 cm proximal to the ulnar styloid over the motor point of the extensor indicis proprius. The first stimulation point (Stim #1) is 4 to 8 cm proximal to the recording electrode in the forearm. The second stimulation point (Stim #2) is in the groove between the biceps and brachioradialis muscles in the elbow. The third stimulation point (Stim #3) is around the spiral groove. (B) Sensory nerve conduction study of the superficial branch of the radial nerve recorded from the anatomic snuffbox. The anatomic snuffbox is best shown by extending and abducting the thumb. The *black arrowhead* shows the medial border formed by the tendon of the extensor pollicis longus. The *white arrowhead* shows the lateral border formed by tendons of the extensor pollicis brevis and abductor pollicis longus.

with stimulation 10 cm proximally at the lateral border of the forearm along the radius. Therefore, the study is only able to document abnormalities in that region. The study may be normal in proximal demyelinating lesions (in approximately 75%–80% of the studies in Mondelli and colleagues<sup>46</sup> and Arnold and colleagues<sup>44</sup>), or demonstrate a prolonged distal motor latency and reduced prolonged conduction velocity if demyelination affects a more distal portion of the nerve.

Axonal loss of sensory nerves is seen more commonly in traumatic radial neuropathies.<sup>46</sup> Axonal loss of sensory nerves, if shown, can be documented by a decrease in the sensory nerve action potential amplitude after 7 to 10 days. If still within the normal range, mild axonal injury may be demonstrated by comparing the sensory nerve action potential amplitude with the normal side to demonstrate a greater than 50% reduction in the side-to-side amplitudes. The absence or presence of the sensory response typically has no bearing on the prognosis of recovery in traumatic radial neuropathies.<sup>45</sup> However, posterior brachial cutaneous sensory nerve conduction studies may have some prognostic value in midforearm lesions.<sup>47</sup> For these studies, the nerve is stimulated at the elbow 2 cm medial to the lateral epicondyle, between the triceps and biceps muscles. The recording electrode is placed 12 cm distal to the stimulating electrode along a line between the stimulation electrode and the mid-dorsum of the wrist.

### Needle EMG

The needle EMG examination is as equally important as nerve conduction in localizing the lesion. Muscles typically studied during needle EMG include, from proximal to distal, the triceps brachii (**Fig. 4A**), brachioradialis (see **Fig. 4B**), extensor carpi radialis (see **Fig. 4C**), extensor digitorum communis (see **Fig. 4D**), extensor carpi ulnaris



**Fig. 4.** Needle EMG insertion sites (*arrowheads*) for radial-innervated muscles. (A) The triceps brachii is tested by extension of the arm against the hand. The insertion site is shown for the lateral head of the triceps. (B) The brachioradialis is tested by flexing the forearm midway between supination and pronation. The insertion site is at the level of the antebrachial cubital fossa. (C) The extensor carpi radialis longus is tested by extending the hand at the wrist while the hand is deviated toward the radius. Flexing or relaxing the fingers and thumb minimizes participation of the digit extensors. The insertion site is two fingerbreadths distal to the lateral epicondyle. (D) The extensor digitorum communis is tested by extension of the middle finger. The insertion site is a third way down the radius and ulna and midpoint between the two. (E) The extensor carpi ulnaris is tested by extending the hand at the wrist while the hand is deviated toward the ulna. The insertion site is at the level of the mid-ulna above its shaft.

(see Fig. 4E), and extensor indicis proprius. Needle EMG of these muscles helps localize the lesion along the radial nerve. The anconeus is also an easily examined muscle but is an extension of the triceps. Because the differential diagnosis includes posterior cord or C7 nerve root lesions, examination of the deltoid, pronator teres, or flexor carpi radialis may also be helpful in localizing the lesions.

Axonal injuries may cause neurogenic findings in time. Demyelinating injuries, such as compression at the midhumeral shaft, cause a reduction in recruitment pattern. However, the distinction between axonal and demyelinating injuries may be best made approximately 4 weeks after the initial injury. As such, a repeat EMG study may be necessary if the initial study was done too early. In one study by Arnold and colleagues,<sup>44</sup> the authors found abnormal spontaneous activity in all patients at least 3 weeks after symptom onset, despite prominent demyelinating features. Mondelli and colleagues<sup>46</sup> also showed abnormal spontaneous activity in 50% of nontraumatic cases and 72% of traumatic cases. In traumatic cases, assessing recruitment in the EMG examination of the brachioradialis may be the most predictive of recovery. In one study, only 33% of patients with absent recruitment had good outcomes, 67% of patients with discrete recruitment had good outcomes, and 92% of patients with full, central, or reduced recruitment had good outcomes.<sup>45</sup> Posterior interosseous neuropathies are better identified by EMG than nerve conduction studies. Interestingly, partial denervation of the extensor carpi radialis can be seen.<sup>38</sup>

## ALTERNATIVE TESTING MODALITIES

Ultrasound is a newer imaging modality that can be useful in localizing lesions, especially compressive masses.<sup>48-51</sup> There are small case series that report ultrasonographic localization of radial nerve swelling in traumatic and nontraumatic radial neuropathy at the spiral groove.<sup>50</sup> Most promising was the ability to diagnose the lesion rapidly after symptom onset. However, these studies are small and require considerable technical expertise. Magnetic resonance neurogram may be another imaging modality that is useful; however, no dedicated studies have been published.

## TREATMENT AND PROGNOSIS

The main management goal of radial neuropathies is to improve hand function. Radial neuropathies at the midhumeral shaft tend to have good prognosis regardless of whether they are demyelinating or axonal. Demyelinating lesions usually improve in 3 months and have an approximately 67% to 100% rate of full recovery.<sup>44,52,53</sup> Axonal injuries caused by closed fracture of the humerus also have a recovery rate around 90%.<sup>21</sup> Therefore, in patients with radial neuropathies associated with fracture of the humeral shaft, the recommendation is to wait for clinical improvement for 2 to 6 months before exploratory surgery of the radial nerve.<sup>21</sup> The recovery of the nerve is similar with early or late repair. A similar approach is recommended for posterior interosseous neuropathies secondary to forearm fractures or orthopedic procedures of the arm or elbow.<sup>54</sup> In these cases, compressive masses deserve surgical exploration.

In severe cases of radial neuropathy where there is no recovery of radial nerve function, tendon transfers or median to radial nerve transfers<sup>55</sup> have been documented to be of benefit. Tendon transfers usually involve transposition of volar-sided tendons to the dorsal compartment through subcutaneous tunnels, and usually involve the pronator teres, flexor carpi ulnaris, palmaris longus, or flexor digitorum communis with the idea of restoring wrist, finger, or thumb extension along with thumb abduction.<sup>56-62</sup>

The main treatment of wrist drop is to provide dorsal wrist cock-up splints with or without dynamic finger extensions. This maintains some hand function, especially ulnar-innervated finger abduction and adduction. Splinting remains the most important intervention, especially because most radial palsies have a good prognosis.

## SUMMARY

Radial neuropathy is a common mononeuropathy of the upper extremity and may be encountered as the result of acute traumatic injuries or fractures, surgical intervention, or compression, which are increased in wartime and inebriation. Clinically, posterior cord plexopathy, cervical radiculopathies, cortical strokes in the precentral “hand knob” area, and focal myopathies may present with similar findings of wrist or finger drop. Electrodiagnostic studies are useful to determine the location and pathologic nature (ie, axonal or demyelinating) of the injury. Electrodiagnostic testing should include motor nerve conduction studies to the extensor indicis proprius, sensory nerve conduction studies of the superficial branch of the radial nerve, and needle EMG of radial-innervated muscles and nonradial muscles supplied by the C7 nerve root. Radial neuropathies associated with humeral mid-shaft fractures or compression lesions in particular generally have a good prognosis.

## ACKNOWLEDGMENTS

The authors thank Carol Teitz, MD, and Dan Graney, PhD, for permission to use their illustration from the University of Washington “Musculoskeletal Atlas: A Musculoskeletal Atlas of the Human Body”. They also thank William T. Kidder for expert help with photography and Dr Glenn Lopate for reviewing the manuscript.

## REFERENCES

1. Radial nerve [online]. Available at: [http://en.wikipedia.org/wiki/Radial\\_nerve](http://en.wikipedia.org/wiki/Radial_nerve).
2. Brazis P, Masdeu J, Biller J. Localization in clinical anatomy. Philadelphia: Lippincott Williams & Wilkins; 2007.
3. Fisch A. Neuroanatomy: draw it to know it. New York: Oxford University Press; 2009.
4. Moore K, Dalley A, AMR A. Clinically oriented anatomy. 6th edition. Baltimore (USA): Lippincott Williams & Wilkins; 2009.
5. Cox CL, Riherd D, Tubbs RS, et al. Predicting radial nerve location using palpable landmarks. *Clin Anat* 2010;23:420–6.
6. Fleming P, Lenehan B, Sankar R, et al. One-third, two-thirds: relationship of the radial nerve to the lateral intermuscular septum in the arm. *Clin Anat* 2004;17: 26–9.
7. de Seze MP, Rezzouk J, de Seze M, et al. Does the motor branch of the long head of the triceps brachii arise from the radial nerve? An anatomic and electromyographic study. *Surg Radiol Anat* 2004;26:459–61.
8. Blackburn SC, Wood CP, Evans DJ, et al. Radial nerve contribution to brachialis in the UK caucasian population: position is predictable based on surface landmarks. *Clin Anat* 2007;20:64–7.
9. Ip MC, Chang KS. A study on the radial supply of the human brachialis muscle. *Anat Rec* 1968;162:363–71.
10. Ji H, Chung I. The muscular branch of the radial nerve to the brachialis muscle in Korean. *Korean J Phys Anthropol* 2002;15:127–31.

11. Mahakkanukrauh P, Somsarp V. Dual innervation of the brachialis muscle. *Clin Anat* 2002;15:206–9.
12. Puffer RC, Murthy NS, Spinner RJ. The spectrum of denervation patterns on MRI reflects the dual innervation of the brachialis. *Clin Anat* 2011;24:511–3.
13. Sunderland S. The intraneural topography of the radial, median and ulnar nerves. *Brain* 1945;68:243–99.
14. Tubbs RS, Salter EG, Wellons JC III, et al. Superficial surgical landmarks for identifying the posterior interosseous nerve. *J Neurosurg* 2006;104:796–9.
15. Dellon AL, Seif SS. Anatomic dissections relating the posterior interosseous nerve to the carpus, and the etiology of dorsal wrist ganglion pain. *J Hand Surg* 1978;3:326–32.
16. Loukas M, Louis RG Jr, Wartmann CT, et al. The clinical anatomy of the communications between the radial and ulnar nerves on the dorsal surface of the hand. *Surg Radiol Anat* 2008;30:85–90.
17. Marathe R, Mankar S, Joshi M, et al. Communication between radial nerve and medial cutaneous nerve of forearm. *J Neurosci Rural Pract* 2010;1:49–50.
18. Pollack L, Davis L. *Peripheral nerve injuries*. New York: Paul B. Hoeber; 1933.
19. Brininger TL, Antozak A, Breland HL. Upper extremity injuries in the U.S. military during peacetime years and wartime years. *J Hand Ther* 2008;21:115–22 [quiz: 123].
20. Carlan D, Pratt J, Patterson JM, et al. The radial nerve in the brachium: an anatomic study in human cadavers. *J Hand Surg* 2007;32:1177–82.
21. Shao YC, Harwood P, Grotz MR, et al. Radial nerve palsy associated with fractures of the shaft of the humerus: a systematic review. *J Bone Joint Surg Br* 2005;87:1647–52.
22. Tuncali BE, Tuncali B, Kuvaki B, et al. Radial nerve injury after general anaesthesia in the lateral decubitus position. *Anaesthesia* 2005;60:602–4.
23. Mouton P, Tardieu S, Gouider R, et al. Spectrum of clinical and electrophysiologic features in HNPP patients with the 17p11.2 deletion. *Neurology* 1999;52:1440–6.
24. Ganapathy K, Winston T, Seshadri V. Posterior interosseous nerve palsy due to intermuscular lipoma. *Surg Neurol* 2006;65:495–6 [discussion: 496].
25. Jou IM, Wang HN, Wang PH, et al. Compression of the radial nerve at the elbow by a ganglion: two case reports. *J Med Case Rep* 2009;3:7258.
26. Malipeddi A, Reddy VR, Kallarackal G. Posterior interosseous nerve palsy: an unusual complication of rheumatoid arthritis: case report and review of the literature. *Semin Arthritis Rheum* 2011;40:576–9.
27. Nishida J, Shimamura T, Ehara S, et al. Posterior interosseous nerve palsy caused by parosteal lipoma of proximal radius. *Skeletal Radiol* 1998;27:375–9.
28. Steiger R, Vogelien E. Compression of the radial nerve caused by an occult ganglion. Three case reports. *J Hand Surg* 1998;23:420–1.
29. Valer A, Carrera L, Ramirez G. Myxoma causing paralysis of the posterior interosseous nerve. *Acta Orthop Belg* 1993;59:423–5.
30. Loh YC, Stanley JK, Jari S, et al. Neuroma of the distal posterior interosseous nerve. A cause of iatrogenic wrist pain. *J Bone Joint Surg Br* 1998;80:629–30.
31. Bowen TL, Stone KH. Posterior interosseous nerve paralysis caused by a ganglion at the elbow. *J Bone Joint Surg Br* 1966;48:774–6.
32. Cravens G, Kline DG. Posterior interosseous nerve palsies. *Neurosurgery* 1990;27:397–402.
33. Dharapak C, Nimberg GA. Posterior interosseous nerve compression. Report of a case caused by traumatic aneurysm. *Clin Orthop Relat Res* 1974;101:225–8.

34. Lallemand RC, Weller RO. Intra-neural neurofibromas involving the posterior interosseous nerve. *J Neurol Neurosurg Psychiatr* 1973;36:991–6.
35. Fernandez E, Pallini R, Lauretti L, et al. Neurosurgery of the peripheral nervous system: the posterior interosseous nerve syndrome. *Surg Neurol* 1998;49:637–9.
36. Campbell WW, Landau ME. Controversial entrapment neuropathies. *Neurosurg Clin N Am* 2008;19:597–608, vi–vii.
37. Sadeh M, Gilad R, Dabby R, et al. Apparent weakness of ulnar-innervated muscles in radial palsy. *Neurology* 2004;62:1424–5.
38. Fardin P, Negrin P, Sparta S, et al. Posterior interosseous nerve neuropathy. Clinical and electromyographical aspects. *Electromyogr Clin Neurophysiol* 1992;32:229–34.
39. Grant AC, Cook AA. A prospective study of handcuff neuropathies. *Muscle Nerve* 2000;23:933–8.
40. Scott TF, Yager JG, Gross JA. Handcuff neuropathy revisited. *Muscle Nerve* 1989;12:219–20.
41. Erdem S, Demirci M, Tan E. Focal myopathy mimicking posterior interosseous nerve syndrome. *Muscle Nerve* 2001;24:969–72.
42. Trojaborg W, Sindrup EH. Motor and sensory conduction in different segments of the radial nerve in normal subjects. *J Neurol Neurosurg Psychiatr* 1969;32:354–9.
43. Negrin P, Fardin P. The electromyographic prognosis of traumatic paralysis of radial nerve. Study of its myelinic and axonal damage. *Electromyogr Clin Neurophysiol* 1984;24:481–4.
44. Arnold WD, Krishna VR, Freimer M, et al. Prognosis of acute compressive radial neuropathy. *Muscle Nerve* 2012;45:893–5.
45. Malikowski T, Micklesen PJ, Robinson LR. Prognostic values of electrodiagnostic studies in traumatic radial neuropathy. *Muscle Nerve* 2007;36:364–7.
46. Mondelli M, Morana P, Ballerini M, et al. Mononeuropathies of the radial nerve: clinical and neurographic findings in 91 consecutive cases. *J Electromyogr Kinesiol* 2005;15:377–83.
47. Lo YL, Prakash KM, Leoh TH, et al. Posterior antebrachial cutaneous nerve conduction study in radial neuropathy. *J Neurol Sci* 2004;223:199–202.
48. Bodner G, Buchberger W, Schocke M, et al. Radial nerve palsy associated with humeral shaft fracture: evaluation with US. Initial experience. *Radiology* 2001;219:811–6.
49. Jacobson JA, Fessell DP, Lobo Lda G, et al. Entrapment neuropathies I: upper limb (carpal tunnel excluded). *Semin Musculoskelet Radiol* 2010;14:473–86.
50. Lo YL, Fook-Chong S, Leoh TH, et al. Rapid ultrasonographic diagnosis of radial entrapment neuropathy at the spiral groove. *J Neurol Sci* 2008;271:75–9.
51. Bodner G, Huber B, Schwabegger A, et al. Sonographic detection of radial nerve entrapment within a humerus fracture. *J Ultrasound Med* 1999;18:703–6.
52. Escolar DM, Jones HR Jr. Pediatric radial mononeuropathies: a clinical and electromyographic study of sixteen children with review of the literature. *Muscle Nerve* 1996;19:876–83.
53. Watson BV, Brown WF. Quantitation of axon loss and conduction block in acute radial nerve palsies. *Muscle Nerve* 1992;15:768–73.
54. Stewart J. Focal peripheral neuropathies. 4th edition. West Vancouver (Canada): JBJ Publishing; 2010.
55. Lowe JB III, Tung TR, Mackinnon SE. New surgical option for radial nerve paralysis. *Plast Reconstr Surg* 2002;110:836–43.
56. Chuinard RG, Boyes JH, Stark HH, et al. Tendon transfers for radial nerve palsy: use of superficialis tendons for digital extension. *J Hand Surg* 1978;3:560–70.

57. Kozin SH. Tendon transfers for radial and median nerve palsies. *J Hand Ther* 2005;18:208–15.
58. Reid RL. Radial nerve palsy. *Hand Clin* 1988;4:179–85.
59. Riordan DC. Tendon transfers for nerve paralysis of the hand and wrist. *Curr Pract Orthop Surg* 1964;23:17–40.
60. Riordan DC. Tendon transfers in hand surgery. *J Hand Surg* 1983;8:748–53.
61. Tsuge K. Tendon transfers for radial nerve palsy. *Aust N Z J Surg* 1980;50:267–72.
62. Krishnan KG, Schackert G. An analysis of results after selective tendon transfers through the interosseous membrane to provide selective finger and thumb extension in chronic irreparable radial nerve lesions. *J Hand Surg* 2008;33:223–31.